

# Global 3-dimensional approach to natural rejuvenation: recommendations for perioral, nose, and ear rejuvenation

Véronique Gassia, MD,<sup>1</sup> Hervé Raspaldo, MD,<sup>2</sup> François-Rene Niforos, MD,<sup>3</sup> & Thierry Michaud, MD<sup>4</sup>

<sup>1</sup> Private Practice, Toulouse, France

<sup>2</sup> Private Practice, Cannes, France

<sup>3</sup> Private Practice, Lyon, France

<sup>4</sup> Private Practice, Mulhouse, France

---

## Summary

**Background** There is a move toward a global, 3-dimensional approach to facial rejuvenation that has been prompted by advances in techniques and available products. However, little published literature exists on the procedures involved in this global approach, and currently, no validated recommendations exist.

**Objectives** To provide a detailed, practical guide to rejuvenation of the perioral area, nose, and ears based on expert consensus recommendations.

**Methods** The aim of this approach was to take into account both volumetric and dynamic aspects of treatment, as well as the benefits of treatment combinations, for example, combining botulinum toxins with hyaluronic acid (HA) fillers and volumizers. Each set of recommendations was documented, comprising a clinical definition of the aging severity scale, together with recommendations of appropriate products, doses, site, depth, and injection techniques, as well as indication-specific rules to be respected.

**Results** HA fillers are ideal for replenishing volume loss in the lips, while rhytides around the lips can be treated with small doses of botulinum toxin. Botulinum toxin can also be used to raise the tip of the nose, to reshape nostrils, and to narrow nasal flare, with HA fillers also be used to correct small defects. HA fillers can also be used to rejuvenate sagging, atrophic or irregular ear lobes, repair torn earlobes, or erase vertical rhytides.

**Conclusions** By providing practical guidance on rejuvenation of the perioral area, nose, and ears, esthetic facial physicians can achieve optimum patient outcomes.

**Keywords:** facial rejuvenation, global approach, perioral, nose, ears

---

## Introduction

In 2010, a panel of experts from the field of esthetic enhancement in France met with the objective of providing practical guidance on the global, tridimensional

approach to natural facial rejuvenation. This panel of experts convened because the introduction of products such as botulinum toxin and hyaluronic acid (HA) fillers, used alone or in combination, has revolutionized treatment of the signs of aging. Furthermore, increased expertise in the field and greater understanding of the physiology of the aging process have prompted a move toward new techniques, specifically a global, 3-dimensional approach<sup>1</sup> comprising muscle relaxation, filling, and volumizing. Importantly, this global approach also

---

Correspondence: Dr V Gassia, 23 Allée Charles-de-Fitte, 31300 Toulouse, France. E-mail: v.gassia@club-internet.fr

Accepted for publication October 17, 2012

takes into account the severity of the signs of aging. However, little published literature on the techniques involved in this approach currently exists, and no validated recommendations on the management of facial rejuvenation have been established to advise esthetic physicians on the best products and injection techniques to use to optimize patient outcomes.

To achieve their aim, the expert group adopted a formalized consensus methodology derived from the Research AND Development (RAND) Corporation,<sup>2</sup> which was developed and validated by the French National Authority for Health (Haute Autorité de Santé [HAS]).<sup>3</sup> This involved establishing an expert Steering Committee to define the methodology and objectives, as well as the most appropriate aging severity scale for each indication. Then, 52 facial rejuvenation experts participated in one of six regional meetings to establish recommendations for rejuvenation of specific facial areas. Only experts with relevant experience in the specific indication under review were invited to participate in the assessment. Statistical validation of results was obtained, and consensus recommendations established.

Two general concepts were validated by the expert panel: (1) the benefits of combining botulinum toxin and hyaluronic acid (HA) and/or volumizing fillers and (2) a treatment plan and its sequence based on an innovative facial segmentation in four esthetic units adjusted by severity stages (see Fig. 1).

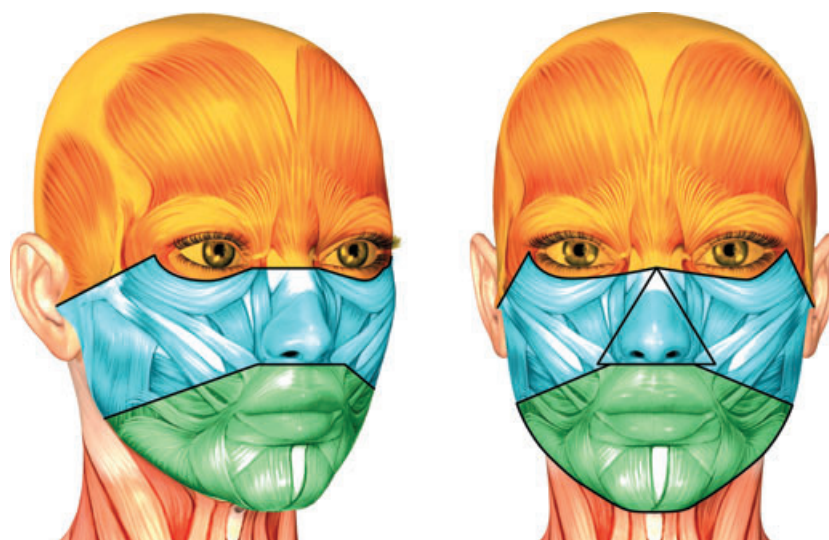The expert consensus group considered it important firstly to volumize the midfacial area, followed by reju-

venation of the eye area, then rejuvenation of the perioral area, and finally, remodeling of other structures (nose and ears) (Fig. 2–3), depending upon patient's needs. This paper focuses on rejuvenation of the perioral area and remodeling of the nose and ears (Fig. 4).

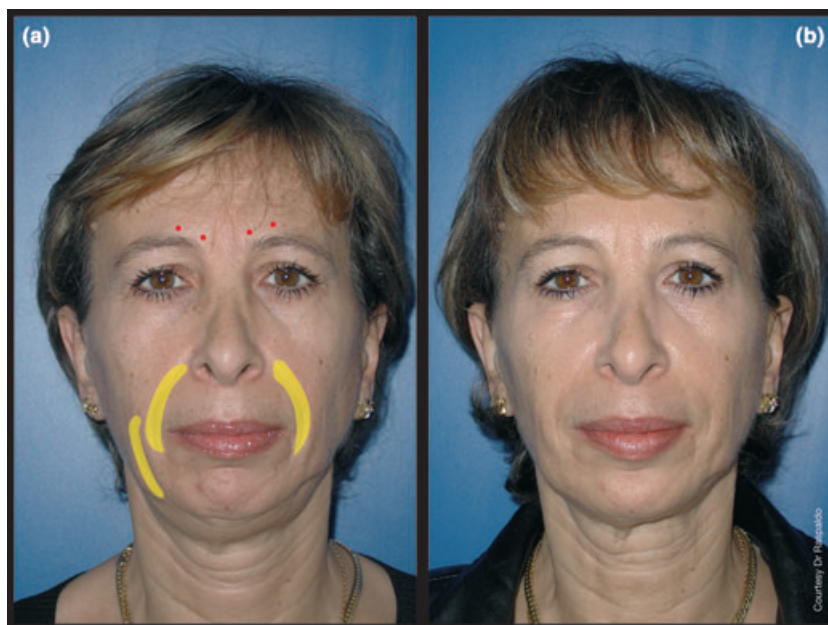## Materials and methods

The consensus process commenced with two experts from the group taking responsibility for establishing methodology and defining objectives. Each expert had at least 20 years' experience with dermal fillers and treat, on average, a minimum of 1500 cases per year, representing in excess of one million procedures. These experts drew on their own extensive experience by initially assessing 20 cases, comprising Caucasian males and females of any age, who were selected according to signs of aging of varying severity and who were then treated with injectable products. These subjects were considered representative of cases seen in clinical practice. Next, a MEDLINE literature review was conducted comprising papers published between 2005 and 2010 investigating approaches to global treatment. A detailed analysis of existing severity rating scales was performed, and the most appropriate scale was selected for each indication according to anatomical site (Table 1, Fig. 5).<sup>4–7</sup>

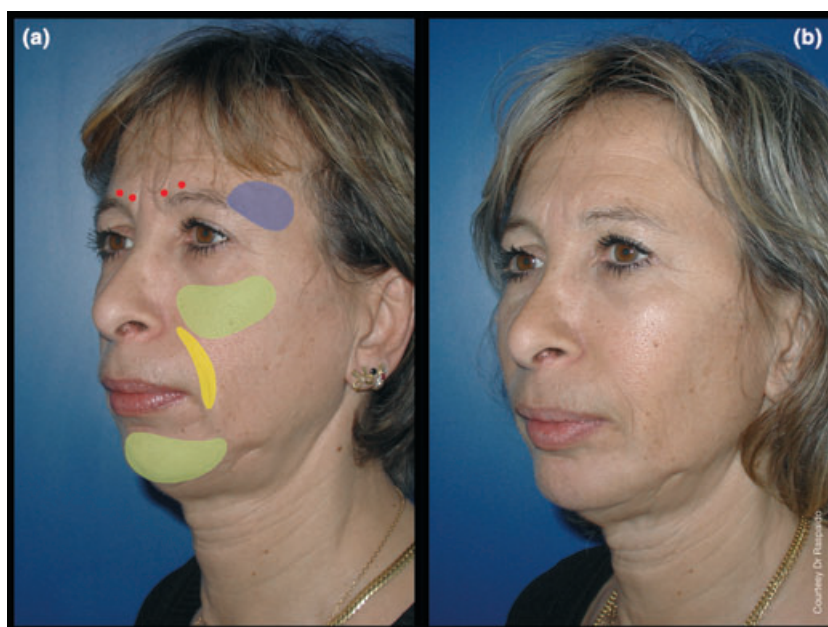Each set of recommendations was documented into separate tables, comprising a clinical definition of the aging severity scale, together with recommendations of appropriate products, doses, site, depth, and injection



**Figure 1** Analytical process: segmentation of the face and aesthetical units. (a) The limit between the upper and the mid units is an oblique line which links the external cantus to the tragus, and which includes the external periorbital area and the Crow's feet in the upper mid unit. Similarly, the limit between the mid and lower units is an oblique line which links the ala of the nose to the gonion, and includes the cheek in the mid unit. (b) The three main aesthetical units are indicated: periocular, mid-face, and perioral area.



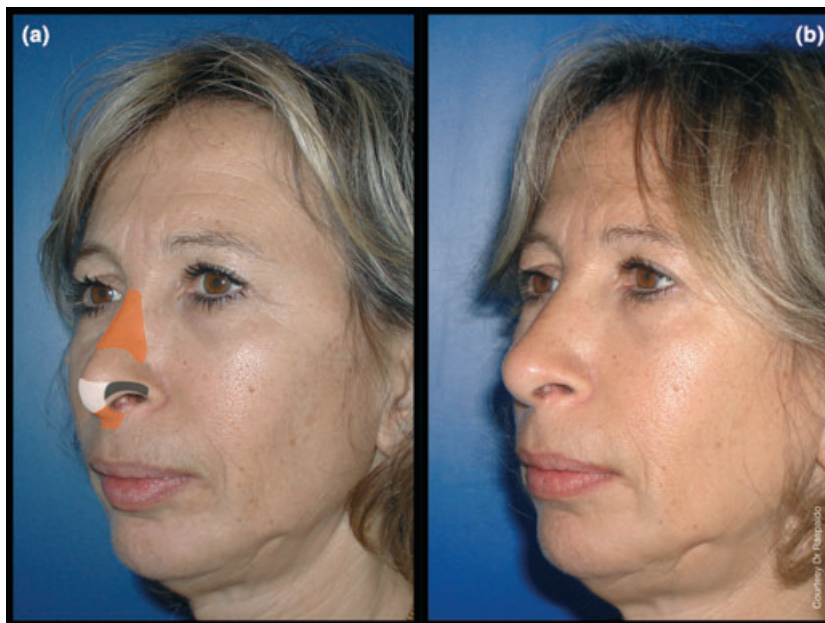**Figure 2** Case study of a global approach - sequence 1. (a) Before treatment. Treatment comprised of 0.6cc Juvederm Ultra 3 per side in nasolabial folds (yellow area) and 5 U OnabotulinumtoxinA per point in the glabella (red area). (b) After treatment.



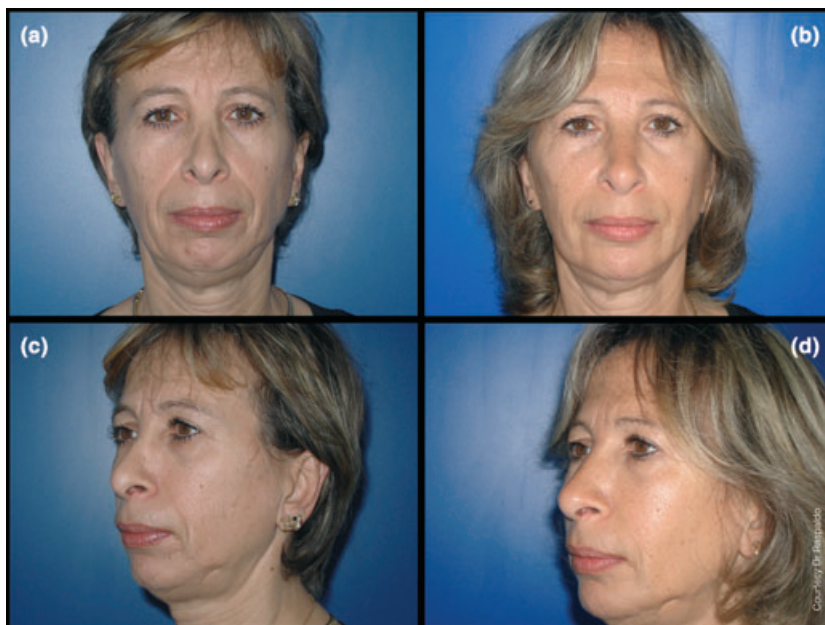**Figure 3** Case study of a global approach - sequence 2. (a) Before treatment. Treatment comprised of 0.4cc Juvederm Ultra 4 in each temple (blue area); 2cc Voluma in each malar-cheek-midface and 2cc Voluma in the chin (green area). (b) After treatment.

techniques, as well as indication-specific rules to be respected and any other comments. To validate the recommendations, the Steering Committee selected 52 experts from the field of facial rejuvenation in France to participate in one of six regional meetings to score the recommendations according to their own clinical

experience. Proposals were rated from 1 (total disagreement) to 9 (full agreement). If the final score was below 7, a new recommendation was proposed and discussed. Only experts with relevant experience in the specific indication under review were invited to participate in each assessment.



**Figure 4** Case study of a global approach - sequence 3. (a) Before treatment. Treatment comprised of 0.6 cc Juvederm Ultra 3 in the dorsum and 0.3 cc Juvederm Ultra 3 in the nasolabial angle (orange area); 0.4 cc Juvederm Ultra 2 in the nasal alar (black area); 0.4 cc Juvederm Ultra 2 in the nasal tip (white area). (b) After treatment.





**Figure 5** Case study of a global approach - sequence 4. (a) and (c) Before treatment. (b) and (d) After treatment.

All results obtained were statistically validated (Table 2). All ratings obtained by the expert committee were analyzed using R v2.11.1 from an algorithm developed by Methodomics. In accordance with HAS recommendations, each item was statistically evaluated

and was considered validated when 85% of participants agreed with the statement or, in the absence of any disagreeing participants, when 80% agreed. The reliability of between-participant agreement for the rating of each item was assessed using the Fleiss Kappa

**Table 1** Severity scales for signs of aging

Anatomical site	Selected scale	Definition of severity stages
Lip remodeling	Description of stages derived from Jacono's scale for the remodeling of lips <sup>4</sup>	Contours = 2 vermillion borders (upper/lower) Body of the lips = 4 quadrants 2 labial commissures Philtrum = 2 philtral columns
Labial rhytides Nasolabial fold Melomental fold (Marionette lines) Jugal rhytides Ears	Lemperlé's Scale for all wrinkles <sup>5</sup>	Scale with definitions and morphed photographic documentation for each anatomical zone Stage 0: No wrinkles Stage 1: Just perceptible wrinkles Stage 2: Shallow wrinkles Stage 3: Moderately deep wrinkles Stage 4: Deep wrinkles, well-defined edges Stage 5: Very deep wrinkles, redundant fold
Mandible and chin	Diagram derived from the publication by Morena Serna <sup>6</sup> Position of chin according to Bell <sup>20</sup>	 <p>When the chin exceeds or is aligned with the vertical line, no treatment is required When the chin sits back from the vertical reference line, the possible treatment outcomes achievable with injectable products can be evaluated</p>
Facial contour	Bazin's classification <sup>7</sup>	Photographic scale Stages 0–5
Nose	A nose scale for facial rejuvenation was difficult to obtain so the consensus group proposed this image with the esthetic zones outlined (note: the esthetic zones must be respected when injecting in this area)	 <p>List of indications:</p> <ul style="list-style-type: none"> <li>• Nasal tip position</li> <li>• Dilated nostrils</li> <li>• Small defect (postsurgical)</li> <li>• Adherences to the nasal dorsum or scars</li> <li>• Flat saddle-shaped dorsum</li> <li>• Protrusion or rotation of the nasal tip</li> <li>• Nasal tip remodeling (heart shape)</li> <li>• Filling of the nasion or of the nasofrontal angle</li> <li>• Nasal deviation</li> </ul>

method. The kappa statistic calculates the nonrandom extent of agreement and is scored between 0 and 1. The interpretation of the kappa value is based on the classification established by Landis and Koch.<sup>8</sup> To assess the statistical significance of the kappa values, 95% confidence interval and *P*-values (corresponding to the null hypothesis  $H_0: K = 0$ ) were provided.

After completion of the statistical analysis, the Steering Committee finalized the consensus recommenda-

tions by integrating these with the findings from the regional boards.

## Results

### Rejuvenation of the mouth

Lip augmentation is an increasingly popular procedure, and esthetic practitioners are continually challenged to

**Table 2** Statistical validation of assessment results and concordance analysis for between-participant agreement for rating of consensus items

Item	No response	Nonindication	Indecision	Indication	Statistical validation HAS	Kappa (K)	P-value	Landis + Koch classification
<b>Peribuccal rejuvenation</b>								
Lip remodeling	0 (0%)	1 (1.92%)	4 (7.69%)	47 (90.38%)	Validated	0.82	<0.001	Excellent
Lips (labial rhytides)	2 (3.85%)	1 (2%)	3 (6%)	46 (92%)	Validated	0.79	<0.001	Good
Nasolabial folds	2 (3.85%)	1 (2%)	1 (2%)	48 (96%)	Validated	0.85	<0.001	Excellent
Marionette lines	2 (3.85%)	1 (2%)	4 (8%)	45 (90%)	Validated	0.75	<0.001	Good
Jugal rhytides	6 (11.54%)	0 (0%)	5 (10.87%)	41 (89.13%)	Validated	0.64	<0.001	Good
Chin – mental fold	25 (53.19%)	0 (0%)	1 (4.55%)	21 (95.45%)	Validated	0.47	<0.001	Moderate
Chin – volumetric reshaping	29 (61.7%)	0 (0%)	1 (5.56%)	17 (94.42%)	Validated	0.48	<0.001	Moderate
Facial contour	19 (36.54%)	0 (0%)	4 (12.12%)	29 (87.88%)	Validated	0.44	<0.001	Moderate
<b>Other structures</b>								
Nose	26 (50%)	0 (0%)	0 (0%)	26 (100%)	Validated	0.49	<0.001	Moderate
Ears	40 (76.92%)	1 (8.33%)	0 (0%)	11 (91.67%)	Validated	0.66	<0.001	Good

Classification of Landis and Koch<sup>6</sup>: Excellent = Kappa value >0.8; Good = Kappa value 0.8–0.6; Moderate = Kappa value 0.4–0.6; Poor = Kappa value 0.2–0.4; Bad = Kappa value 0–0.2; Random = Kappa value 0; Negative = Kappa value <0.

devise techniques suited to meet individual patient requirements.<sup>9</sup> Despite the sensitivity of the lips, it is now relatively easy to administer many injections into this area due to surgeons using tiny 30 and 31 gauge needles, as well as incorporation of topical or injectable anesthesia into treatment regimens.<sup>10</sup> However, to achieve a more youthful perioral area, it is important to consider shaping the lips, not just simply adding volume.<sup>1</sup> There are several aspects to be considered when rejuvenating the lips such as redefining the vermilion border, replenishing lost volume,<sup>11–14</sup> and degree of poutiness.<sup>13</sup> Hyaluronic acid fillers are ideal for replenishing volume loss and re-establishing a pleasing esthetic look comprising well-proportioned and voluminous lips,<sup>1,11</sup> while rhytides around the lips can be treated with small doses of botulinum toxin to weaken the lip sphincter and smooth the wrinkles.<sup>15</sup> Interestingly, it has been found that treatment of the lips and the perioral area is more frequently performed to prevent the effects of lip aging and for treatment of dynamic lip rhytides in conjunction with other forms of esthetic treatments.<sup>16</sup>

#### Lip remodeling (Table 3)

The expert consensus group concluded that lip remodeling should be conducted following an anatomical evaluation of each patient. Treatment should then be personalized according to the individual needs of each anatomical zone, based on Jacono's simplified and practical classification system.<sup>4</sup> The consensus group agreed that the treatment strategy should comprise replenishment of lost lip volume<sup>1,11,13,15</sup> and improvement of

lip contour and relief,<sup>1,11,13,15</sup> followed by a combination of volume and lip contour restoration.<sup>1</sup> It is important to exercise caution during treatment to avoid overcorrection. Newer volumizing products containing lidocaine reduce the need for use of conventional anesthetic techniques and so are recommended. Anti-herpes preventative treatment can be used if required.


#### Labial rhytides (Table 3)

The expert consensus group was in accord with the published literature regarding correction of labial rhytides. This should be performed using a combination of fillers and botulinum toxin (up to a maximum of 4 U for the upper lip), with botulinum toxin also being used in the vermilion border at the anatomical junction between the red and white lips. However, it is important to avoid overcorrection.

#### Nasolabial folds (Table 4)

Nasolabial folds should be treated depending upon baseline severity using a tracing or retro-tracing technique. A cannula rather than a needle can be used for HA filler administration at all stages. Different HA products that have differing rheological characteristics can also be combined to optimize the results. It is important to note that while volume restoration to the midfacial middle third does not eliminate the need to treat nasolabial folds, it does significantly decrease the severity stage. It is important that augmentation of the proximal nasolabial folds with fillers is performed with caution as there is a risk of vascular compromise of the angular artery.

**Table 3** Lip remodeling and labial rhytides

	Lip remodeling	Labial rhytides	
Stage/indication	Based on the anatomical evaluation of each subject, treatment is personalized according to the needs of each defined anatomical zone using the following systematized drawing (adapted from Jacono's publication [6]):		
			
	Border: 2 vermilion borders (lower and upper) Body of the lip: 4 quadrants 2 labial commissures Philtrum: 2 philtral columns		
Example Products	JU2 or Juvéderm Ultra Smile	JU2 or Juvéderm Hydrate	OnabotulinumtoxinA
Dose	Vermilion borders: 0.3–0.4 mL/border Quadrants (red lip): 0.2–0.3 mL for each quadrant Labial commissures: 0.1–0.3 mL/side Philtrum: 0.1–0.2/side	0.4–0.6 mL	1 U per site Maximum total of 4 U for the upper lip as first-line treatment
Sites	Vermillion borders, quadrants, labial commissures, and philtrum (see diagram)	White lips	4 injection points for the upper lip 2–4 injection points for the lower lip
Injection technique	Injection means: 27–30G needle or 27–30G cannula Depth of injection: Vermillion borders: injection in the virtual space between the orbicularis oris muscle and the cutaneous plane Quadrants (red lip): intramuscular or sub-mucous injection Labial commissures: subcutaneous injection Philtrum: subcutaneous injection Injection modality: Tracing and/or retro-tracing	Injection means: 27–30G needle or 27–30G cannula Depth of injection: Intradermal or subcutaneous (cannula) Injection modality: Tracing and/or retro-tracing or nappage	Hypodermic injection 2 alternative techniques: Recommended technique: Injection in the vermilion border, at the anatomical junction between red and white lips Alternative technique: injections at a slightly wider distance (at 2 mm above the upper lip vermilion border and at 2 mm below the lower lip vermilion) in the middle of the plicature, in cases of very dynamic wrinkles, as demonstrated during pronunciation of an "E" or an "O"
Rules to be respected	Avoid overcorrection	Avoid overcorrection	
Comments	Anti-herpes prevention if needed		

*Melomental fold (Table 4)*

Correction of the melomental fold can best be treated using a combination of botulinum toxin and HA fillers, which together provide an adjunctive effect. HA fillers should be administered 2 weeks after the botulinum toxin injection but, again, it is important to avoid overcorrection.

*Jugal wrinkles (Table 5)*

The expert consensus group recommends a comprehensive approach to jugal wrinkle treatment that allows a more personalized approach to achieve optimum

results. Until recently, patients tended to request that treatment is limited to the nasolabial folds and lips; however, it is now possible to take a more global approach by incorporating jugal wrinkle correction into the overall treatment plan. Treatment of jugal wrinkles should be performed using a combination of HA fillers and botulinum toxin, which together have a synergistic effect. The consensus group suggests use of a cannula and combined treatment comprising botulinum toxin into the risorius muscle and HA filler in the cheek wrinkles. However, it should be noted that this is an emerging technique with little evidence currently

**Table 4** Nasolabial folds and melomental fold

		Nasolabial folds				Melomental fold	
Stage/indication	1	2-3	4-5	1-3 with dynamic component	1-3	4-5	
Example Products	JU3	JU3 or 4	JU3 or 4 Voluma	OnabotulinumtoxinA	JU2 or 3	JU4, Voluma	
Dose	0.3-0.4 mL per side	0.4-0.8 mL per side	0.8 mL or more per side	In upper position: 1-2 U per injection point In lower position: 2 U per injection point 1 injection point in each DAO muscle	0.2-0.4 mL per side	JU4: 0.4-0.8 mL per side Voluma: 0.3-0.5 mL per side	
Sites	Nasolabial fold				In the melomental fold		
Injection technique	Injection means: 27-30G needle Depth of injection: Subcutaneous injection ± intradermal injection ± intradermal injection modality: Tracing and/or retro-tracing	Injection means: 27-30G needle Depth of injection: Subcutaneous injection ± intradermal injection ± intradermal injection modality: Tracing and/or retro-tracing	Injection means: 27G needle or 25-27G cannula Depth of injection: Subcutaneous injection ± intradermal injection ± intradermal injection modality: Tracing and/or retro-tracing	2 alternative techniques: For the upper position: superficial hypodermic injection (in a point located horizontally at 1 cm of the mouth corner and vertically at 2 cm below this horizontal line) For the lower position: superficial injection, on the horizontal line passing 1 cm above the mandibular edge and at the crossing with the line passing through the nasal ala and the labial commissure	Injection means: 27-30G needle or 27-30G cannula Depth of injection: Subcutaneous injection ± intradermal injection ± intradermal injection modality: Tracing and/or retro-tracing or in a fanning scheme (cannula)	Injection means: 23-27G needle or 23, 25, 27G cannula Depth of injection: Subcutaneous injection ± intradermal injection modality: Tracing and/or retro-tracing or in a fanning scheme (cannula)	
Rules to be respected				Filling 2 weeks after OnabotulinumtoxinA injection	Avoid overcorrection		
Comments				Adjunctive effects of the two types of products			



**Table 5** Jugal wrinkles and chin

Jugal wrinkles		Chin	
Stage/indication	1–3	4	1–2 with a dynamic component and a satisfactory cutaneous elasticity
Example Products	JU2 ± Juvéderm Hydrate	JU3 or 4	OnabotulinumtoxinA
Dose Sites	0.3–1 mL per side The cheek	≥0.8 mL per side	2 U per side In the risorius muscle at 2 cm on the horizontal line passing through the labial commissures
Injection technique	Injection means: 30G needle or 27–30G cannula Depth of injection: Intradermic or subcutaneous injection Injection modality: Fanning, tracing or retro-tracing injections, or nappage Avoid overcorrection	Injection means: 27G needle or 25–27G cannula Depth of injection: Subcutaneous injection Injection modality: Fanning, tracing or retro-tracing injections, or nappage	OnabotulinumtoxinA: For the “peau” fillers and OnabotulinumtoxinA <sup>13</sup> HA: HA dermal fillers; <sup>12</sup> any type of HA but those with a long duration are more suitable (Voluma® or Sub-Q®); Voluma® <sup>11,17,18</sup> OnabotulinumtoxinA: Dimpled chin (peau d’orange), mentalis: 1 to 2 (start with 1 midline or 2 symmetrical, lateral injections) <sup>1</sup> HA: Serial puncture or linear threading injection techniques; <sup>1,17</sup> for minor advancement, use a combination of highly cross-linked collagen (1.6 mL) and large particle HA (1.75 mL) injected into all layers up to the periosteum <sup>15</sup>
Rules to be respected	Adjunctive and synergistic effects of the two types of products		
Comments	Adjunctive and synergistic effects of the two types of products		

available in the literature on the treatment of cheek wrinkles. Product choice and dose depends upon baseline severity stage. Modest treatment of stage five jugal wrinkles is possible with careful expert consideration.

#### *Chin (Table 5)*

Remodeling of the chin, particularly the lateral regions that become hollow with aging,<sup>11,17</sup> has limited results. However, chin enhancement using dermal fillers may be helpful in some cases.<sup>15</sup> Dermal fillers should be injected using a needle or cannula, although HA fillers with a long duration can be injected using serial puncture or linear threading techniques.<sup>11,17,18</sup> Botulinum toxin administered as one midline or two symmetrical lateral injections for chin rejuvenation does show some benefits.<sup>1</sup> These treatments can be used in correcting irregular chin contours, such as “peau d’orange” or “cobblestoning.”<sup>13</sup> For minor chin enlargement, a combination of highly cross-linked

collagen (1.6 mL) and large particle HA (1.75 mL) should be injected into all layers as far as the periosteum.<sup>15</sup> HA fillers are also useful for smoothing the appearance of chin implants, particularly in the transition area between the implant and soft tissue layer.<sup>1</sup> The skin over the chin implant may dimple, and this can be addressed using approximately botulinum toxin into the mentalis.<sup>1</sup> Filling this area allows reshaping of the oval facial outline or jawline.<sup>17</sup> The expert consensus group concludes that the use of HA fillers for chin remodeling can prove a successful and long-lasting treatment.<sup>11</sup>

#### *Facial contours (Table 6)*

Facial contouring is in general a rare indication, with modest results obtained from treatment. The expert consensus group does not favor facial contouring in patients presenting with a heavier lower face. However, remodeling of the chin, particularly, the lateral

**Table 6** Facial contours

Facial contours			
Stage/indication	Platysma	Hypertrophic masseters	Facial contour Stages 1 to 3
Example Products	OnabotulinumtoxinA	OnabotulinumtoxinA	Juvéderm Voluma or JU4
Dose	2 U per injection point. Dose is adjusted to muscle tonicity. Maximum dose of 50 U for the entire neck.	Total dose of 18–30 U in each masseter muscle	0.8–1 mL per side and per session
Sites	Delineate the anterior and posterior chords in dynamic state, then inject every 2 cm vertically on these reference marks	1 to 5 injection points	In the notch located in the posterior chin part and the anterior part of the jawl
Injection technique	2 to 4 injection points per chord Hold the chords between 2 fingers, then inject intramuscularly. Treat all the chords if possible in only one session	Delimit the anterior and posterior edges of the masseter muscles, while asking the patient to tighten the jaws The injection points are localized at the level of the lower half of the muscle, using a hypodermic 30G needle. The injection points are at a minimum of 1 cm of the muscle edges and under a line drawn from the lowest part of the external auditory meatus to the central part of the upper lip Intramuscular injection as far as bone contact, perpendicular to the cutaneous plane	At the level of the mandibular edge Injection means: 27G needle or 23–25G cannula Depth of injection: Deep subcutaneous injection Injection modality: Tracing and/or retro-tracing injections
Rules to be respected			Avoid overcorrection, which gives a heavy look to the facial contour. Avoid pricking the facial artery at the level of its crossing with the mandibular edge
Comments	Rare indication with modest results		

regions that become hollow with aging, is of great importance. Filling this area permits reshaping of the oval outline of the face (jawline).<sup>17</sup> Stages 1–3 are best treated using HA fillers, as these are best suited to reshaping and contouring atrophied jowls by lifting and tightening the sagging cutaneous tissues that occur with aging.<sup>11</sup> However, it is important to avoid over-correction, which gives the face a heavy facial contour, and it is also important to avoid pricking the facial artery at the point where it crosses with the mandibular edge. Botulinum toxin is recommended for treatment of the platysma and hypertrophic masseters.

#### Rejuvenation of other structures (nose and ears)

More rarely documented in the literature is the use of botulinum toxin to raise the tip of the nose, to reshape nostrils, and to narrow nasal flare;<sup>17</sup> however, it can be a useful treatment in this area. HA or other fillers can also be used to correct small defects, such as those occurring spontaneously or secondary to surgical rhinoplasty.<sup>1,11,15</sup> Furthermore, HA fillers can be used to rejuvenate sagging, atrophic or irregular ear lobes,<sup>1,12</sup> repair torn earlobes,<sup>1</sup> or erase vertical rhytides.<sup>12</sup>

#### Nose (Table 7)

Treatment of the nose with botulinum toxin and HA fillers is an emergent indication with few publications, but numerous oral communications on the subject. Due to this lack of documented guidance, the expert consensus group has provided practical treatment recommendations with suitable indications and product doses (Table 7). It is important to note that the esthetic zones outlined in Table 1 must be respected while injecting. It is important that any augmentation post-rhinoplasty is performed with caution due to the risk of compromised vascularity.

- *Tip position:* Raising the nose tip position can be performed with botulinum toxin injected into the depressor septi nasi<sup>17</sup> or nose tip.<sup>1</sup> If the tip drops with smiling, botulinum toxin can be injected into the depressor of the septum.<sup>15</sup>
- *Dilated nostrils:* Nostril reshaping can be performed by weakening the dilator nasi with small doses of botulinum toxin.<sup>15</sup> Botulinum toxin injections into the levator labii superioris alaeque nasi and into the dilator nasi<sup>15</sup> can help to narrow nasal flare, while expansion of nasal flare can be performed using HA products.<sup>15</sup>
- *Remodeling:* HA injections into the nasal ridge can be used to correct small defects<sup>17</sup> or postrhinoplas-

**Table 7** Nose

Nasal indications		Small defect (postsurgical)	Adherence to nasal dorsum or scars	Flat saddle-shaped dorsum	Protrusion or rotation of the nasal tip	Nasal tip remodeling (heart shape)	Filling of the nasion or nasofrontal angle	Nasal deviation
Stage/indication	Nasal tip position	Dilated nostrils	Adherence to nasal dorsum or scars	Flat saddle-shaped dorsum	Protrusion or rotation of the nasal tip	Nasal tip remodeling (heart shape)	Filling of the nasion or nasofrontal angle	Nasal deviation
Example Products	OnabotulinumtoxinA	OnabotulinumtoxinA	JU3 or 4	JU3 or 4 or Voluma	JU3 or 4	JU3 or 4	JU3 or 4	JU3 or 4 or Voluma
Dose Sites	2–4 U at injection point 1 central injection point at the level of the nasal spine in the depressor septi nasi muscle	1–2 U per injection point in the dilator naris muscle	0.1–0.3 mL	0.3–1 mL	0.3–0.8 mL	0.1–0.4 mL	0.1–0.3 mL	0.3–1 mL
Injection technique	Deep injection perpendicular to the nasal spine	Subcutaneous injection						
Rules to be respected		Injection means: 27–30G needle or 25–27G cannula Depth of injection: Subcutaneous injection Injection modality: Tracing and/or retro-tracing injections or fanning injections						
Comments		Respect the esthetic zones while injecting. Any augmentation postrhinoplasty to be performed with caution due to the risk of compromised vascularity. Be particularly careful with the volume of doses in patients wearing glasses						

ty defects,<sup>15,17</sup> as well as to recontour the nasal dorsum and tip due to surgical depression or atrophic changes caused by aging.<sup>1</sup> HA can also be used after rhinoplasty for refinement or to treat drooping that occurs with aging.<sup>1</sup> Treatment comprises elevation of the nasal tip by injecting botulinum toxin into the nasal spine area and into the lower nasalis.<sup>1</sup> Suitable sites of administration comprise elevation of the nose saddle, recontouring the nasal tip, and injecting filler at the base of the columella to lift the entire nasal tip.<sup>1</sup> The recommended injection technique comprises HA fluid injected through a thin 30G needle without the use of anesthesia;<sup>17</sup> however, it is important to note that excessive filling of cartilaginous dorsum irregularities may cause supra-tip deformation.<sup>15</sup> Enhancement is immediate and lasts a long time, depending on the choice of injected HA product.<sup>17</sup> It should be noted that smaller amounts of filler are needed if the patient has thin skin.<sup>15</sup> For more extensive nose reshaping, filling the anterior nasal spine and the columella base with collagen opens the nasolabial angle from 90° to 110°.<sup>15</sup>

#### Ears (Table 8)

Irregularities in the ears are seen as impediments to overall esthetic beauty.<sup>12</sup> Treatment comprises the use of fillers and resurfacing of the vertical rhytides immediately anterior to the ear and earlobe,<sup>12</sup> while HA fillers can be used to fill sagging earlobes and rejuvenate appearance.<sup>1</sup> Injection should be via a 27–30G needle using a combination of serial threading and serial puncture.<sup>12</sup> The filler can be injected directly into the lobe and massaged into place to avoid lumping and to provide fullness to the lobe;<sup>12</sup> however, care should be taken to respect the overall esthetic appearance. Treat-

**Table 8** Ears

Stage/indication	Ear indications	
	Auricular lobule wrinkles	Auricular lobule curve
Example	JU2 or 3	JU3 or 4
Products		
Dose	0.2 mL per lobule	0.2–0.4 mL per lobule
Sites	The lobule	
Injection technique	Injection means: 27–30G needle Depth of injection: Intradermic or subcutaneous injection	Injection means: 27–30G needle Depth of injection: Subcutaneous injection
	Injection modality: Tracing and/or retro-tracing injections	Injection modality: Tracing and/or retro-tracing injections

ment effects are very long-lasting, which may be due to the lack of movement and metabolic activity in this region.<sup>1</sup>

## Discussion

Definitive treatment guidelines are seen as an important clinical tool in the quest to deliver optimum patient care based on the best possible scientific evidence.<sup>19</sup> While advances in the field of esthetics have prompted a move toward global, 3-dimensional treatments, there is currently little published literature on the techniques involved in this approach. To address this, the expert panel of esthetic physicians in France has provided recommendations on a wide variety of facial areas, with this paper focusing on providing detailed, practical advice on the perioral, nose, and ear rejuvenation. The perioral area is particularly important area to correct for most patients, as plump, full lips are seen as a sign of youth, whereas thin, wrinkled lips are considered representative of old age.<sup>10</sup>

The expert panel adopted a rigorous, systemic methodology, which considered the identification and severity of the specific facial aging signs to be corrected based on published, or generally accepted, rating scales. For each indication, the most appropriate scale was selected by an expert Steering Committee and recommendations were developed accordingly. Thus, patient management has been adapted to the severity stage of aging signs for each facial area. All recommendations made by the expert consensus group with respect to rejuvenation of the perioral area, nose, and ears were statistically validated according to French National Authority for Health (HAS) guidelines, and the reliability of between-participant agreement for the rating of consensus items was assessed using the Fleiss Kappa method according to the classification established by Landis and Koch.<sup>8</sup> These methodologies were used to ensure that the recommendations were robust and could be considered validated.

The expert consensus group used a comprehensive, tridimensional approach that encompasses three types of products: botulinum toxin, dermal fillers, and volumizers, used either alone or in combination. The beneficial synergistic effects of combination treatments were also discussed and recommended where appropriate. This global, coordinated approach allows optimization of results by achieving a balanced, natural looking, harmonious face, which satisfies patient requirements. This then leads to improved patient quality of life,<sup>13</sup> as well as contributing to enhanced inner well-being and psychological balance for the patient.

In conclusion, the expert consensus group recommendations provide a detailed, practical guide to rejuvenation of the perioral area, nose, and ears based on validated findings. It is anticipated that these recommendations will prove a useful reference for esthetic facial physicians so they can achieve optimum patient outcomes.

## Acknowledgments

Funding for this study was provided by Allergan.

## Members of the Expert Consensus Group

### Lille

Sandrine Boivin, Jean-Christophe Bouchez, Alexandre Capon, Francois Caprioni, Thierry Fontaine, Patrick Fontet, Marie-Laure Hamon, Freddy Lengrand, Anne Roumazelle, Isabelle Rousseaux (moderator), and Francine Velly Mores.

### Lyon

Joël Ankin, Martine Baspeyras, Michel Corniglion, Benoit Dardart, Nicole Dejeammes, Hugues Giffon, Nicolas Gounot, Xavier Martinet, Francois Niforos (moderator), and Dominique Serre.

### Marseille

Richard Abs, Jean-Paul Cayatte, Anne Collet, Regis Corbier, Fred Germain, Michèle Giraudeau, Jean-Luc Jauffret, and Hervé Raspaldo (moderator).

### Paris

Soraya Benamor, Catherine Bergeret-Galley, Anne Couder, Gérard Flageul, Olivier Galatoire, François Niforos (moderator), Jean-Marie Pozzo, Marc Runge, and Michel Tazartes.

### Strasbourg

Vanessa Bollecker, Michel David, Agnès Ehlinger, Jean-Pascal Fyad, Thierry Michaud (moderator), Denis Perrin, Catherine Raimbault, Pierre-Thomas Schmitt, and Marie-Pierre Schwartzann.

### Toulouse

Martial Bodnar, Philippe Denis, Véronique Gassia (moderator), Pascale Grolleau, Corinne Guegantou, Nathaniel Khalifa, Christophe Marecaux, Catherine Richard, Geneviève Samalens, Laurent Soubirac, and Paul Touron.

## References

- 1 Carruthers JD, Glogau RG, Blitzer A. Advances in facial rejuvenation: botulinum toxin type A, hyaluronic acid dermal fillers, and combination therapies - consensus recommendations. *Plast Reconstr Surg* 2008; **121**(5 Suppl): 5S-30S.
- 2 Brook RH. The RAND/UCLA appropriateness method. In: KA McCormick, SR Moore, RA Siegal, eds. *Clinical Practice Guideline Development Methodology Perspectives*. Rockville, Maryland: US Department of Health and Human Services; 1994: pp. 59-70.
- 3 Haute Autorité de Santé. Bases méthodologiques pour l'élaboration de recommandations professionnelles par consensus formalisé 2006. Available from [http://www.has-sante.fr/portail/plugins/ModuleXitiKLEE/types/File-Document/doXiti.jsp?id=c\\_269978](http://www.has-sante.fr/portail/plugins/ModuleXitiKLEE/types/File-Document/doXiti.jsp?id=c_269978).
- 4 Jacono AA. A new classification of lip zones to customize injectable lip augmentation. *Arch Facial Plast Surg* 2008; **10**: 25-9.
- 5 Lemperle G, Holmes RE, Cohen SR, Lemperle SM. A classification of facial wrinkles. *Plast Reconstr Surg* 2001; **108**: 1735-50; discussion 51-52.
- 6 Morera Serna E, Scola Pliega E, Ulldermolins NM *et al*. Treatment of chin deformities. *Acta Otorrinolaringol Esp* 2008; **59**: 349-58.
- 7 Bazin R, Doublet E. Ptôse ou affaissement de l'ovale du visage. In: R Bazin, E Doublet, eds. *Atlas du vieillissement cutané*. Paris: Med'Com; 2007: pp. 56-7.
- 8 Landis JR, Koch GG. The measurement of observer agreement for categorical data. *Biometrics* 1977; **33**: 159-74.
- 9 Clymer MA. Evolution in techniques: lip augmentation. *Facial Plast Surg* 2007; **23**: 21-6.
- 10 Lanigan S. An observational study of a 24 mg/mL hyaluronic acid with pre-incorporated lidocaine for lip definition and enhancement. *J Cosmet Dermatol* 2011; **10**: 11-4.
- 11 Brandt FS, Cazzaniga A. Hyaluronic acid gel fillers in the management of facial aging. *Clin Interv Aging* 2008; **3**: 153-9.
- 12 Matarasso SL, Carruthers JD, Jewell ML. Consensus recommendations for soft-tissue augmentation with nonanimal stabilized hyaluronic acid (Restylane). *Plast Reconstr Surg* 2006; **117**: 3S-34S; discussion 35S-43S.
- 13 Wise JB, Greco T. Injectable treatments for the aging face. *Facial Plast Surg* 2006; **22**: 140-6.
- 14 Rohrich RJ, Ghavami A, Crosby MA. The role of hyaluronic acid fillers (Restylane) in facial cosmetic surgery: review and technical considerations. *Plast Reconstr Surg* 2007; **120**(6 Suppl): 41S-54S.
- 15 de Maio M. The minimal approach: an innovation in facial cosmetic procedures. *Aesthetic Plast Surg* 2004; **28**: 295-300.
- 16 Raspaldo H, Niforos F, Gassia V, *et al*. Lower-face and neck anti-aging treatment and prevention using botulinum toxin A: the 2010 multidisciplinary

- French consensus. *J Cosmet Dermatol* 2011; **10**: 131–49.
- 17 Andre P. New trends in face rejuvenation by hyaluronic acid injections. *J Cosmet Dermatol* 2008; **7**: 251–8.
- 18 Raspaldo H, Aziza R, Belhaouari L, et al. How to achieve synergy between volumetry, filling products and botulinum toxin for global facial rejuvenation. *J Cosmet Laser Ther* 2011; **13**: 77–86.
- 19 Rycroft-Malone J. Formal consensus: the development of a national clinical guideline. *Qual Health Care* 2001; **10**: 238–44.
- 20 Bell WH, McBride K. Genioplasty strategies. In: WH Bell ed. *Modern Practice in Orthognathic and Reconstructive Surgery*. Philadelphia: Saunders; 1985: pp. 2439–88.