

# Guidelines for the management of vitiligo: the European Dermatology Forum consensus

A. Taieb,<sup>1</sup> A. Alomar,<sup>2</sup> M. Böhm,<sup>3</sup> M.L. Dell'Anna,<sup>4</sup> A. De Pase,<sup>5</sup> V. Eleftheriadou,<sup>6</sup> K. Ezzedine,<sup>1</sup> Y. Gauthier,<sup>1</sup> D.J. Gawkrödger,<sup>7</sup> T. Jouary,<sup>1</sup> G. Leone,<sup>4</sup> S. Moretti,<sup>8</sup> L. Nieuweboer-Krobotova,<sup>9</sup> M.J. Olsson,<sup>10</sup> D. Parsad,<sup>11</sup> T. Passeron,<sup>12</sup> A. Tanew,<sup>13</sup> W. van der Veen,<sup>9</sup> N. van Geel,<sup>14</sup> M. Whitton,<sup>15</sup> A. Wolkerstorfer<sup>9</sup> and M. Picardo<sup>4</sup>; the writing group of the Vitiligo European Task Force (VETF) in cooperation with the European Academy of Dermatology and Venereology (EADV) and the Union Européenne des Médecins Spécialistes (UEMS)

<sup>1</sup>Service de Dermatologie, CHU de Bordeaux, Bordeaux Cedex, France

<sup>2</sup>Institut Universitari Dexeus, Universitat Autònoma Barcelona, Barcelona, Spain

<sup>3</sup>Department of Dermatology, University of Münster, Münster, Germany

<sup>4</sup>San Gallicano Dermatologic Institute, IRCCS, Roma, Italy

<sup>5</sup>ARIV, Bergamo, Italy

<sup>6</sup>Centre of Evidence Based Dermatology, University of Nottingham, Nottingham, U.K.

<sup>7</sup>Department of Dermatology, Royal Hallamshire Hospital, Sheffield, U.K.

<sup>8</sup>Division of Clinical Preventive and Oncologic Dermatology, University of Florence, Florence, Italy

<sup>9</sup>Department of Dermatology, Netherlands Institute for Pigment Disorders, AMC/University of Amsterdam, Amsterdam, the Netherlands

<sup>10</sup>Department of Medical Sciences, Dermatology and Venereology, Uppsala University, Uppsala, Sweden

<sup>11</sup>Department of Dermatology, PIGMER, Chandigarh, India

<sup>12</sup>Department of Dermatology, Université de Nice-Sophia Antipolis, Nice, France

<sup>13</sup>Department of Dermatology, Vienna General Hospital, Vienna, Austria

<sup>14</sup>Department of Dermatology, Ghent University Hospital, Ghent, Belgium

<sup>15</sup>The Cochrane Skin Group, Centre for Evidence Based Dermatology, University of Nottingham, Nottingham, U.K.

## Summary

### Correspondence

Mauro Picardo.

E-mail: picardo@ifo.it

### Accepted for publication

25 July 2012

### Funding sources

None.

### Conflicts of interest

None declared.

DOI 10.1111/j.1365-2133.2012.11197.x

The aetiopathogenic mechanisms of vitiligo are still poorly understood, and this has held back progress in diagnosis and treatment. Up until now, treatment guidelines have existed at national levels, but no common European viewpoint has emerged. This guideline for the treatment of segmental and nonsegmental vitiligo has been developed by the members of the Vitiligo European Task Force and other colleagues. It summarizes evidence-based and expert-based recommendations (S1 level).

Vitiligo is an acquired depigmenting disorder affecting 0.5% of the world population, without sex or racial differences. It affects all age groups.<sup>1,2</sup> According to the consensus definition given to generalized/vulgaris or nonsegmental vitiligo (NSV) by the Vitiligo European Task Force (VETF)<sup>1</sup> 'vitiligo vulgaris/NSV is an acquired chronic pigmentation disorder characterized by white patches, often symmetrical, which usually increase in size with time, corresponding to a substantial loss of functioning epidermal and sometimes hair follicle melanocytes'; however, this is not specific enough. It needs to be completed by a list of disorders (the acquired generalized hypomelanoses) which may clinically overlap with NSV, but which

are clearly attributable to known aetiological factors. In cases of uncertain diagnosis, additional noninvasive and invasive procedures may be needed (Table 1).

Segmental vitiligo (SV) is defined descriptively as for NSV except for a unilateral distribution (asymmetric vitiligo) that may totally or partially match a cutaneous segment (e.g. dermatomal-like). Some specific features of SV are rapid onset and involvement of the hair follicle pigmentary system. One unique segment is involved in most patients (Table 2).

Concerning therapy and NSV topographic subtypes, acral lesions show the worst response rate.<sup>3</sup> Distinction between SV and NSV may affect prognosis in terms of resistance to

repigmentation. Other forms of vitiligo (such as mucosal or eyelid vitiligo) may necessitate specific approaches not detailed in depth in this guideline.

In terms of therapy, the immune-mediated inflammatory phase of vitiligo needs to be better defined in order to develop specific approaches targeted to this important phase of the disease pathogenesis. This phase is mostly silent and only revealed when skin biopsies are taken at the margins of progressing lesions. Stable vitiligo needs a treatment to regenerate the melanocytes from hair follicle or interfollicular precursors.

In the assessment steps it is important to consider age, pre-existing diseases, in particular autoimmune disorders, previous medications, and objective and subjective parameters (Table 3).<sup>4-6</sup> As the care often extends over a long period of time, patients are frequently frustrated by the failure of previous treatments. Psychological stress is common. The treatment plan should be discussed with the patient to obtain a high level of compliance. It must be remembered that some therapies are not licensed for vitiligo and can only be prescribed 'off-label'.<sup>6</sup>

**Table 1** Recommended diagnostic procedures in vitiligo

If diagnosis is certain	If diagnosis is uncertain
Anti-TPO, antithyroglobulin antibodies	Punch biopsy from lesional and nonlesional skin
TSH and other tests if needed to assess thyroid function or diagnosis (e.g. anti-TSHR antibodies if Graves disease)	Other tests if needed (mycology, molecular biology to detect lymphoma cells, etc.)
Additional autoantibodies (only if patient's history, family history and/or laboratory parameters point to a strong risk of additional autoimmune disease), endocrinologist/immunologist advice if multiple autoimmune syndrome detected	

TPO, thyroid peroxidase; TSH, thyroid-stimulating hormone; TSHR, TSH receptor.

**Table 2** Classification of vitiligo<sup>1</sup> and specific features of the vitiligo subtypes

Type of vitiligo	Subtypes	Remarks
NSV	Focal, <sup>a</sup> mucosal, acrofacial, generalized, universal	Subtyping may not reflect a distinct nature, but useful information for epidemiological studies
SV	Focal, mucosal, uni-, bi- or plurisegmental	Further classification according to distribution pattern possible, but not yet standardized
Mixed (NSV + SV)	According to severity of SV	Usually the SV part in mixed vitiligo is more severe
Unclassified	Focal at onset, multifocal asymmetrical nonsegmental, mucosal (one site)	This category is a meant to allow, after a sufficient observation time (and, if necessary, investigations), a definitive classification to be made

NSV, nonsegmental vitiligo; SV, segmental vitiligo. <sup>a</sup>Possible onset of NSV.

**Table 3** Evaluation checklist for the management of patients with nonsegmental vitiligo

Patient features	Disease features	Family	Interventions
Phototype	Duration (patient's opinion: progressive, regressive, stable over the last 6 months)	Premature hair greying	Type and duration of previous treatments, including opinion of patient (list): useful/not useful
Ethnic origin	Previous repigmentation, Koebner phenomenon	Vitiligo autoimmune disease (family tree)	Current treatment(s)
Age at onset	Genitals involvement photographs (if possible ultraviolet photographs)		Treatments (list) for other diseases
Psychological profile			
Halo naevus			
History of autoimmune diseases			
Global QoL assessment (10 cm visual analogue scale)			

QoL, quality of life. The table was adapted from Ref. 1 and 2.

If the patient's history or routine laboratory parameters suggest additional autoimmune disorders, further investigations and specialist advice (e.g. in the case of autoimmune polyglandular syndrome) are strongly suggested (Table 1).

This guideline for the treatment of SV and NSV vitiligo has been developed by the members of the VETF and other colleagues. It summarizes evidence-based and expert-based recommendations (S1 level).

## Topical corticosteroids

Topical corticosteroids (TCS) have been applied since the 1950s for their anti-inflammatory and immunomodulating effects. As first-line treatment for limited forms of vitiligo TCS and topical calcineurin inhibitors (TCI) are now widely used.<sup>7</sup>

### Efficacy

Topical corticosteroids have the best results (75% of repigmentation) on sun-exposed areas (face and neck),<sup>8,9</sup> in dark skin<sup>10</sup> and in recent lesions.<sup>11</sup> Acral lesions respond poorly. In a meta-analysis of nonsurgical therapies for vitiligo, modest, but significant effectiveness was shown with a success rate of 33% (16/48) vs. 0% (0/48) in the placebo groups.<sup>8</sup> No differences in efficacy were found between clobetasol and tacrolimus,<sup>12</sup> and between clobetasol<sup>13</sup> or mometasone<sup>14</sup> and pimecrolimus, although TCI might be less effective for extrafacial lesions. When used in the short term, TCS appear to be safe and effective treatment for both children and adults.<sup>7</sup>

Local side-effects (skin atrophy, telangiectasia, hypertrichosis, acneiform eruptions and striae) of potent or very potent TCS are well known. Lower potency classes of TCS and newer class III TCS, such as mometasone furoate and methylprednisolone aceponate, are largely devoid of these side-effects.

Currently, there are no studies available on optimal duration of TCS therapy and on discontinuous applications that could improve the therapeutic index.<sup>7</sup>

#### Expert recommendations: TCS

- In children and adults, once-daily application of potent TCS can be advised for patients with limited, extrafacial involvement for a period no longer than 3 months, according to a continuous treatment scheme or, better, to a discontinuous scheme (15 days per month for 6 months with a strict assessment of response based on photographs).
- Facial lesions can be treated as effectively and with lesser side-effects by TCI.
- As potent TCS appear to be at least as effective as very potent TCS, the first category should be the first and safest choice.
- Systemic absorption is a concern when large areas of skin, regions with thin skin and children are treated for a prolonged time with potent steroids. TCS with negligible systemic effects, such as mometasone furoate or methylprednisolone aceponate, should be preferred.

## Calcineurin inhibitors

Since 2002 the beneficial effects of TCI have been reported, particularly in areas where prolonged use of potent TCS is contraindicated.<sup>15</sup> Tacrolimus and pimecrolimus are topical ascomycin immunomodulating macrolactams (TIM) and act as TCI, affecting the activation/maturation of T cells and subsequently inhibiting the production of cytokines, such as tumour necrosis factor (TNF)- $\alpha$ .<sup>16</sup> Moreover, the enhancement of melanocyte migration and differentiation has been described.<sup>17</sup>

### Efficacy

Only a few randomized trials have been published,<sup>12,18–21</sup> showing beneficial results mainly in the head and neck region, both in adults and children. Ultraviolet (UV) radiation exposure during TIM treatment may play a synergistic role,<sup>22</sup> but long-term safety studies are not available. Controversy exists about the possibility of TIM inducing repigmentation on UV-protected areas or areas over bony prominences.<sup>12,23,24</sup>

Two randomized, double blind, left–right comparative trials showed that tacrolimus offers similar results compared with clobetasol propionate 0.05% in the treatment of children.<sup>12,25</sup> Pimecrolimus could be considered as an alternative treatment to clobetasol.<sup>13</sup> In an open, randomized study comparing topical pimecrolimus and tacrolimus, Stinco *et al.*<sup>26</sup> did not detect significant differences in the efficacy. In another open study, Lotti *et al.*<sup>27</sup> showed a slightly higher response rate in patients treated with tacrolimus (61%) than in those treated with pimecrolimus (54.6%). Finally, a case report described, in a head-to-head comparison, similar repigmentation of pretibial lesions by tacrolimus and pimecrolimus when used under occlusion overnight.<sup>28</sup> One open study suggest that tacrolimus could be effective even in SV.<sup>29</sup>

Data about the most effective treatment scheme are still needed. Twice-daily applications of tacrolimus ointment have shown more efficacy than once-daily applications.<sup>26</sup> Duration ranged from 10 weeks up to 18 months. Information about the minimal or ideal treatment period and the usefulness of long-term intermittent use is not available.

### Tolerance

The most common early reported side-effects for TIM are local reactions (burning sensation, pruritus and erythema).<sup>12,18–23</sup> Although rare, transient skin hyperpigmentation has also been reported.<sup>30</sup> The association between TIM and UV or sun exposure is currently not recommended, according to the 'black box' warning of the U.S. Food and Drug Administration for atopic dermatitis. Long-term studies are reassuring for atopic dermatitis but still lacking for vitiligo, which is an off-label prescription in most countries.

#### Expert recommendations: TIM

- TIM can be considered in adults and children with vitiligo as an alternative to topical steroids for new, actively

spreading, lesions on thin skin. The topical safety profile of TIM is better compared with potent TCS, especially concerning risks of skin atrophy.

- Considering that data from double-blind placebo-controlled studies are limited, and that efficacy of TIM is not clearly demonstrated on other sites without occlusion, the use of TIM should be restricted to selected areas, in particular the head and neck region.
- Twice-daily applications are recommended. The treatment should be prescribed initially for 6 months. During this period of treatment, moderate but daily sun exposure should be recommended. If effective, prolonged treatment (e.g. longer than 12 months) may be proposed, as side-effects of long-term use of TCI are reassuring in other conditions such as atopic dermatitis.

## Phototherapies

### Photochemotherapies

Photochemotherapy with psoralen plus UVA radiation (PUVA) combines the use of psoralens with long-wave (320–340 nm) UVA radiation. Photochemotherapy with khellin plus UVA radiation (KUYA) combines the use of khellin with long-wave (320–340 nm) UVA radiation. Psoralens can be given orally or topically (solutions, creams or bath) followed by exposure to UVA. PUVA-induced stimulation of melanogenesis involves the photoconjugation of psoralens to DNA leading to proliferation of melanocytes, increased synthesis of tyrosinase, formation and melanization of melanosomes, and increased transfer of melanosomes to keratinocytes.<sup>31–33</sup>

### Narrowband ultraviolet B and targeted phototherapies

Narrowband UVB radiation (NB-UVB, 311 nm) currently represents the phototherapy of choice for active and/or widespread vitiligo. Side-effects are less frequent than in PUVA therapy and efficacy is at least equivalent.<sup>34,35</sup> Targeted phototherapy devices (excimer laser or lamp) deliver light in the UVB range (peak at 308 nm) and are particularly suitable for treating localized disease.<sup>36</sup>

### Efficacy

#### Photochemotherapies

Repigmentation is noted in 70–80% of patients with PUVA, but complete repigmentation is obtained in only 20% of patients. Relapse can occur in 75% of patients after 1 or 2 years. It is not recommended in children aged under 10–12 years because of the risk of retinal toxicity. For oral PUVA, 8-methoxypsoralen (8-MOP; 0.6–0.8 mg kg<sup>-1</sup>), 5-methoxypsoralen (5-MOP; 1.2–1.8 mg kg<sup>-1</sup>) or trimethylpsoralen

(0.6 mg kg<sup>-1</sup>) is given orally 1–3 h before exposure to UVA. Patients should be motivated to continue PUVA therapy for at least 6 months before being considered nonresponsive, and 12–24 months of continuous therapy may be necessary to acquire maximal repigmentation. Darker skin types show maximal responses to PUVA and maximal repigmentation occurs in patients achieving erythema grade 2.<sup>34,37,38</sup>

For topical PUVA, a thin coat of 8-MOP cream or ointment at very low concentration (0.001%) should be applied 30 min before UVA exposure, with possible further concentration increments. The advantage of topical therapy is the need for fewer treatments and considerably smaller cumulative UVA doses, as well as lower plasma levels and consequently less systemic and ocular phototoxicity.<sup>39</sup> The main disadvantages are severe blistering reactions, perilesional hyperpigmentation and lack of effectiveness in limiting the progression of actively spreading vitiligo.

Another photochemotherapy regimen, KUYA, consists of khellin as the photosensitizer, a furanochrome extracted of the plant *Amni visnaga* (5,8-dimethoxy-2 methyl-4,5-furo-6,7 chromone) and UVA.<sup>40,41</sup> KUYA's lack of phototoxicity makes it safe for use as a home treatment or treatment with natural sunlight, even in a daily regimen. It is also less mutagenic than psoralens and it promotes less darkening of normal skin. Khellin is given orally at 100 mg 2 h before treatment. The efficacy rate of this treatment can be compared with PUVA, but is limited because approximately 30% of patients present liver toxicity (cytolysis). Khellin can also be topically applied in a moisturizing cream or carbopol gel at a concentration of 3–5%. Systemic KUYA has nowadays been largely abandoned. Topical 'KUYA-sun' is still sometimes used in sunny countries; however, its efficacy in comparison with oral PUVA or other therapeutic modalities has not been established.

### Narrowband ultraviolet B total body and targeted therapies

Narrowband UVB is easy to perform but a proper dosimetry is mandatory to achieve optimal treatment results. Patients with vitiligo have traditionally been regarded as skin type I and consequently were treated with very low initial NB-UVB doses (150–250 mJ cm<sup>-2</sup>). However, minimal erythemal dose (MED) values in vitiligo skin are on average only 35% (95% confidence interval 31–39%) lower than in normal skin of the same individual, suggesting photoadaptation.<sup>42–46</sup> Treatment is usually given twice or three times weekly and is continued as long as there is ongoing repigmentation. The extent and the disease activity at onset of treatment do not seem to affect the likelihood of repigmentation.

Narrowband UVB appears to be more effective than other phototherapies. A randomized, double-blind trial confirmed the higher efficacy of NB-UVB vs. oral PUVA (8-MOP or 5-MOP) in 50 patients with NSV. At the end of the study, the PUVA group had received a mean number of 47 treatments as opposed to 97 treatments in the NB-UVB-group. Sixty-four per cent of patients in the NB-UVB group had 50% or more

improvement compared with 36% of patients in the PUVA group. Moreover, among the patients with more than 48 sessions of treatments, the reduction of depigmented surface area was significantly greater for NB-UVB than for PUVA. The colour match of repigmented skin was excellent in all patients treated with NB-UVB but in only 44% of those treated with PUVA. Accordingly, NB-UVB was superior to oral PUVA, and most treatment centres currently consider NB-UVB as the first-line treatment for NSV.<sup>38</sup> Moreover, 5-MOP is currently unavailable, further limiting the use of PUVA therapy. Only a few long-term follow-up studies have investigated the persistence of repigmentation after discontinuation of NB-UVB, showing relapse rates of 21% and 44% within 1 year, and 55% within 2 years.

New therapeutic devices deliver high fluency light, laser or incoherent, selectively to the lesions.<sup>47–51</sup> High energy monochromatic light sources provide rapid induction of repigmentation, and fewer treatments are required to achieve repigmentation compared with conventional NB-UVB. A recent study demonstrated the greater efficacy of the 308-nm excimer laser treatment over NB-UVB in producing a more rapid and intense repigmentation.<sup>51</sup>

### Tolerance of phototherapies

The long-term risk of skin cancer is well established for PUVA. NB-UVB, as well as targeted UVB phototherapies, are well tolerated. The most common acute adverse reaction is skin type- and dose-dependent erythema, usually occurring 12–24 h after irradiation, continuing within another 24 h and disappearing before the next treatment session. Thus, it is essential to ask the patients whether, and to what extent they have developed erythema in response to the previous irradiation. A slight erythema reaction in lesional skin is generally considered a good guideline for adequate dosimetry. Higher doses are commonly applied with targeted phototherapies. Therefore, erythematous reactions may occur more often and with greater intensity than with NB-UVB. However, these reactions are confined to small areas of the treated skin and do not impair the general well-being of the patient.

Data supporting the safety of phototherapies in childhood are limited, and caution is recommended.

#### Expert recommendations: phototherapies

##### Photochemotherapies (PUVA, KUVA)

- Oral PUVA is currently used in adult patients with generalized vitiligo as a second-line therapy. Compared with NB-UVB it has the disadvantage of lower efficacy and higher short- and long-term risks. As with NB-UVB, 12–24 months of continuous therapy may be necessary to acquire maximal repigmentation. For topical PUVA, psoralens should be formulated in creams at very low concentration.

- Oral KUVA has been largely abandoned due to significant liver toxicity. Topical khellin might be combined with artificial UVA irradiation or exposure to natural sunlight. However, randomized controlled studies assessing the efficacy of this approach are lacking.

##### NB-UVB and targeted phototherapies

- NB-UVB is indicated for generalized NSV. Total body treatment is suggested for lesions involving more than 15–20% of the body area. Total NB-UVB has also been considered as treatment for active spreading vitiligo, even if limited supportive data are available. Targeted phototherapies (laser and nonlaser) are indicated for localized vitiligo and in particular for small lesions of recent onset and childhood vitiligo, to avoid side-effects due to total body irradiation with UVB, and in all cases where contraindications exist for total body irradiation with conventional NB-UVB (risk for melanoma or nonmelanoma skin cancer, photoaggravated disease, etc.). There is as yet no consensus as to the optimum treatment duration of NB-UVB or targeted phototherapy. Many therapists tend to stop irradiation if no repigmentation occurs within the first 3 months of treatment or in case of unsatisfactory response (< 25% repigmentation) after 6 months of treatment. Phototherapy is usually continued as long as there is ongoing repigmentation or over a maximum period of 1 or 2 years. Maintenance irradiation is not recommended, but regular follow-up examinations are suggested for detecting relapse.

### Combination treatments

Several combination treatments have been proposed with the aim of interacting with different pathogenic aspects of the disease and to potentiate the possibility of repigmentation. Several trials have demonstrated that combined treatments improve the overall effectiveness and the time needed to achieve repigmentation reducing the potential side-effects. Moreover, this strategy has been proposed in subjects with lesions refractory or resistant to monotherapies. Combinations of phototherapies with different topical or systemic drugs have been evaluated as well as the combination of surgical and medical treatments.

A prospective, randomized, controlled, left–right comparison study showed that the combination of UVA and topical fluticasone propionate was more effective than UVA or topical steroid alone.<sup>9</sup> Combining the 308 nm excimer laser with topical hydrocortisone 17-butyrate cream showed significantly higher repigmentation than the laser alone in a prospective trial performed for resistant head and neck lesions.<sup>52</sup>

The efficiency of 308 nm excimer plus tacrolimus was greater compared with laser treatment alone.<sup>21</sup> Side-effects

were limited to constant erythema and, rarely, bullous lesions. These encouraging results have been corroborated by other reports for the combination of UVB radiation and topical tacrolimus.<sup>53–55</sup> The combination of pimecrolimus and NB-UVB also appears promising.<sup>56</sup> However, the possible increased risk of skin cancers promoted by the association of two immunosuppressants needs to be taken into consideration. Calcipotriol with natural sunlight or PUVA might be useful. However, the efficacy has not been clearly established and data are still controversial.<sup>57–59</sup> Calcipotriol treatment used with the 308 nm excimer laser was recently evaluated in a short prospective study;<sup>60</sup> it did not increase the efficacy of the 308 nm excimer laser. Tacalcitol, even at high concentration (20 µg g<sup>-1</sup>), in combination with excimer laser has shown limited effect in a prospective single-blinded study.<sup>61</sup> Calcipotriol plus corticosteroids improved the onset, the degree and the stability of the repigmentation in children.<sup>62</sup>

The combination of topical pseudocatalase with UV radiation has shown very promising results in a pilot nonrandomized controlled trial: complete repigmentation on the face and the dorsum of the hands was seen in 90% of patients. Two subsequent studies failed to confirm these data.<sup>63,64</sup>

Oral antioxidant supplementation was reported to increase slightly the effectiveness of UVB in two prospective double-blind placebo-controlled studies.<sup>65,66</sup> However, larger studies are required to confirm these data.

NB-UVB was also used with laser dermoabrasion in resistant areas. Despite the reported improved efficacy of NB-UVB, the conflicting data about the possible side-effects affect the routine clinical practice.<sup>67</sup> The association of NB-UVB with fractional CO<sub>2</sub> laser could be effective in refractory areas as reported in a small randomized left–right comparative trial.<sup>68</sup>

In a prospective study, Anbar *et al.*<sup>69</sup> concluded that prior use of erbium-YAG laser skin ablation, followed by 5-fluorouracil (5FU) application may improve the outcome of short-term NB-UVB therapy.

Psoralen plus UVA radiation after surgical treatment enhances the repigmentation rate.<sup>70,71</sup> The combination of NB-UVB with surgical therapies has been less extensively studied but also enhances repigmentation. A prospective, randomized, double-blind study clearly showed that autologous transplanted epidermal cell suspensions followed by NB-UVB or PUVA was superior to phototherapy alone.<sup>72</sup> No direct comparison between NB-UVB and PUVA, as a synergistic agent for surgical grafting, is currently available.

In a prospective study, the combination of punch grafting with a topical steroid (fluocinolone acetonide 0.1%) was as effective as punch grafting followed by PUVA.<sup>73</sup> Open studies and case reports suggest that low doses of oral steroids might be beneficial in addition to surgical procedures.

Low-dose azathioprine (at the maximal dosage of 50 mg daily) in combination with PUVA vs. PUVA alone was evaluated in a randomized trial.<sup>74</sup> The mean total repigmentation after 4 months of therapy was higher in the patients who received azathioprine plus PUVA (58.4%) compared with

PUVA alone (24.8%). Nausea was reported as a side-effect in two patients receiving azathioprine.

### Expert recommendations: combination therapies

- **Topical steroids and phototherapy** The anti-inflammatory properties of the steroids may act on the immune/inflammatory component, mainly in recent and active lesions, lowering the total amount of administered UV radiation. Although prospective studies are still lacking, the combination of TCS and UVB sources (NB-UVB and 308 nm excimer lasers or lamps) may be promising for difficult-to-treat areas, e.g. over bony prominences. Potent topical steroids applied once a day (3 weeks out of 4) can be used on vitiligo lesions for the first 3 months of phototherapy.
- **TCI and phototherapy** There is good evidence that the combination of TCI and UV radiation is effective and provides better results than the two treatments used alone. Although increasing data suggest that the combination of UV and topical TCI is safe, long-term data on carcinogenicity are still lacking.
- **Vitamin D analogues and phototherapy** The use of vitamin D analogues in combination with UV radiation is not recommended as the benefit of the combination therapy appears to be at best very limited.
- **Phototherapy and other treatments** The antioxidant supply may act by restoring the intracellular redox status, intrinsically and UV compromised. The association of phototherapy and oral antioxidants might be beneficial but the preliminary need to be confirmed before such a combination can be recommended.
- **Phototherapy after surgery** There is now a good level of evidence that phototherapy (NB-UVB or PUVA) should be used for 3 or 4 weeks after surgical procedures to enhance repigmentation.

## Oral steroids and other immunosuppressants

### Oral steroid minipulse therapy

Studies on systemic steroids have been sparingly reported in the literature. Pulse therapy refers to the intermittent administration of large (suprapharmacological) doses to enhance the therapeutic effect and reduce the side-effects of a particular drug. Oral minipulse (OMP) of moderate doses of betamethasone/dexamethasone has been pioneered in India by Pasricha *et al.*<sup>75</sup> Systemic steroids can arrest the activity of the disease,<sup>75–79</sup> but are not effective in repigmenting stable vitiligo. Moreover side-effects associated with long-term use of daily systemic corticosteroids contraindicate their common use. In these first reported studies,<sup>76,77</sup> betamethasone or dexamethasone was given as a single oral dose of 5 mg on two consecutive days per week. In adult nonresponders to the standard

dose of corticosteroids, the dose was increased to 7.5 mg daily and then reduced to 5 mg daily when disease progression was arrested. Within 1–3 months of treatment, 89% of patients with progressive disease stabilized, while within 2–4 months, repigmentation was observed in 80% of the patients. The area of repigmentation continued to progress as treatment continued, although none of the patients achieved complete repigmentation. Radakovic-Fijan *et al.*<sup>77</sup> used dexamethasone minipulses of 10 mg daily on two consecutive days per week up to 24 weeks. Disease activity was arrested in 88% of patients with progressive disease after 18.2 weeks of treatment. Side-effects (weight gain, insomnia, agitation, acne, menstrual disturbances and hypertrichosis) were observed in 69% of patients. Overall, OMP with either betamethasone or dexamethasone can arrest, without inducing repigmentation, the progression of vitiligo. During fast-spreading vitiligo, phototherapy is usually commenced after this intervention. However, there are no randomized clinical trials (RCTs) confirming that either speed or magnitude of response to phototherapy and photochemotherapy might be potentiated by concomitant administration of OMP.

### Other immunosuppressants and biologics

Immunosuppressants other than oral steroids have been evaluated in a limited number of studies. Anecdotal reports also exist on the off-label use of some immunomodulating biologics in vitiligo.

#### Cyclophosphamide

Cyclophosphamide ( $2 \times 50$  mg daily) was assessed in a small case study of 33 patients. In 29 patients, some repigmentation was seen including acral sites.<sup>80</sup> Side-effects included hair loss, cytopenia and nausea. Quality of life was not recorded and further details of this case study are not available.

#### Ciclosporin

Systemic ciclosporin ( $6 \text{ mg kg}^{-1}$  daily) was tested in six patients.<sup>81</sup> Little or no repigmentation was seen in five out of six patients after several months of therapy. Detailed information on the treated patients is not available. The most prominent side-effects were renal dysfunction and hypertension.

#### Antitumour necrosis factor- $\alpha$

A case study assessed the therapeutic potential of etanercept in a small open-label pilot study of four patients with progressive NSV.<sup>82</sup> Etanercept 50 mg was given weekly for 12 weeks, followed by 25 mg weekly for a further 4 weeks. Although tolerability was good, none of the patients had a repigmentation response. In another case report,<sup>83</sup> a patient with ankylosing spondylitis and progressive NSV was treated with infliximab (350 mg infliximab intravenously in weeks 0, 2 and 6, and

then every other week for 10 months). After 6 months, spreading of vitiligo stopped and partial or complete repigmentation occurred on several spots. However, NSV may be induced by anti-TNF- $\alpha$  agents.<sup>84</sup>

### Expert recommendations: OMP and other immunosuppressants

- OMP therapy is not considered useful for repigmenting stable vitiligo.
- Weekend OMP starting with low doses (2.5 mg daily) of dexamethasone for fast-spreading vitiligo can be considered, with a good tolerance profile.
- The benefit of adding OMP to phototherapy at the onset of treatment in progressive vitiligo is not proven and needs further assessment.
- The optimal duration of OMP therapy needed to stop vitiligo progression is between 3 and 6 months.
- Current data do not provide enough evidence to recommend immunosuppressants or biologics in patients with vitiligo. Moreover, the potential side-effects of these agents do not justify their use in vitiligo.

### Other systemic interventions: antioxidants

The occurrence of cellular oxidative stress during the progression of vitiligo is the rationale for the topical or systemic administration of antioxidants.<sup>85</sup> Pseudocatalase, vitamin E, vitamin C, ubiquinone, lipoic acid, *Polypodium leucotomos*, catalase/superoxide dismutase combination, and *Ginkgo biloba* are antioxidants that have been used alone or, more frequently, in combination with phototherapy. The administration of antioxidants during or before phototherapy aims to counteract the oxidative stress induced by UV radiation itself, increasing its effectiveness.

#### Efficacy

Open trials suggested that oral or topical administration of single or multiple antioxidants stopped the progression of the disease and promoted repigmentation.<sup>86</sup> RCTs reported to date suggest that vitamin E is effective for the recovery of skin lipid peroxidation induced by PUVA treatment.<sup>87</sup> A mixture of  $\alpha$ -lipoic acid, and vitamins E and C, administered in a double-blind placebo-controlled trial, promoted a reduction of UV dosage together with improvement of the repigmentation.<sup>65</sup> *Polypodium leucotomos*, an antioxidant photosensitizing and immunomodulator agent, was effective when used in association with PUVA or UVB.<sup>66</sup> *Ginkgo biloba*, a polyphenol compound with anti-inflammatory, immunomodulatory and antioxidant activities, also showed promising results. However, the number of enrolled patients is limited and outcome parameters are inconsistent.<sup>88–90</sup> No side-effects have been reported but long-term administration has raised concerns.<sup>91</sup>

**Expert recommendations: antioxidants**

- Antioxidant supplementation could be useful during UV therapy, and during the reactivation phase of vitiligo. However, RCTs evaluating systemic antioxidant supplements provide a limited evidence of efficacy, and further confirmation is needed before recommending their prescription in vitiligo.

**Surgery**

Surgical procedures aim to replace the melanocytes with ones from a normally pigmented autologous donor site. Several melanocyte transplantation techniques can be performed under local anaesthesia in an outpatient facility. However, transplantation for extensive areas may require general anaesthesia. All methods require strict sterile conditions.<sup>92–99</sup>

Punch grafting (tissue graft) is the easiest and least expensive method, but it is not suitable for large lesions and seldom produces even repigmentation.

Epidermal blister grafting gives excellent cosmetic results, but it is time-consuming, and large areas cannot be treated.

Ultrathin epidermal sheet grafting can treat larger areas (up to 200 cm<sup>2</sup>) but requires skill and experience.

Cellular grafts consist of a basal cell layer autologous suspension containing melanocytes and keratinocytes. A given area can be treated with a good donor to recipient ratio. Initially, this procedure required a laboratory facility for cell processing, but single-use kits for enzymatic separation of thin shave biopsies from the graft area have been developed, allowing the generation of cell suspension in the operating room within 1 h.

Transplants of pure cultured melanocytes expanded *in vitro* can treat lesions up to 500 cm<sup>2</sup>. This method is more expensive, time-consuming and requires specialized staff.

The highest incidence of adverse events occurs with punch grafting (scar formation at the donor site, cobblestoning of the acceptor area) followed by ultrathin epidermal grafting (transient or permanent hypopigmentation, hypertrophic scars on the donor site, milia formation on the recipient site) and suction blister epidermal grafting (transitory hyperpigmentation on donor site, imperfect colour matching on the recipient site).<sup>95</sup> Rare side-effects (temporary depigmentation at donor site and transitory inflammatory hyperpigmentation at recipient site) have been observed with cellular grafting. Follow-up studies have documented long-term stability and safety.<sup>94</sup>

Although surgery is normally indicated for all types of stable vitiligo, only a small number of patients with vitiligo are suitable. The best indications are stabilized segmental or focal vitiligo, mainly when SV is characterized by leucotrichia and large lesional areas.<sup>99</sup> In NSV various recommendations suggest a period of disease inactivity ranging from 6 months to 2 years, and no history of a Koebner isomorphic response. No consensus exists concerning the minimal age for surgery, which is generally

performed under local anaesthesia.<sup>92,95–97</sup> It has to be stressed that surgery does not change the overall prognosis of the disease in the case of NSV. When a surgical treatment is conducted in NSV it should be combined with other medical and or UV-light treatment for best outcome and long-term stability.

**Expert recommendations: surgery**

- The surgery option should be reserved for patients with SV and other localized forms of vitiligo, after the documented failure of medical interventions.
- For NSV, patients with the stable form of the disease and a negative history of Koebner phenomenon are eligible, but the risk of relapse must be explained thoroughly to the patient.

**Other interventions****Camouflage**

Considering the impact of the disease on the patient's self-body image, camouflage techniques are an important part of the global management of the disease.<sup>100–104</sup> Products developed to disguise aesthetic skin disfigurement, require specialized application techniques.<sup>100,101</sup> There is a wide choice of self-tanning agents, stains, dyes, whitening lotions, tinted cover creams, compact, liquid and stick foundations, fixing powders, fixing sprays, cleansers, semipermanent and permanent tattoos, and dyes for pigmenting facial and scalp white hairs.<sup>103</sup> Permanent camouflage, micropigmentation and tattoos should be considered with particular caution,<sup>104</sup> due to the unpredictable course of the vitiligo.

**Expert recommendations: camouflage**

- *Self-tanning agents in gel, cream, lotion or spray* These give the skin a brown colour that resembles a natural tan and normally lasts from 3 to 5 days; they can be used throughout the year and are waterproof, and the fake tan developed does not stain clothes or sheets. Unluckily, seawater makes them fade quickly, while swimming pool water does not.
- *Highly pigmented cover creams* These are lightweight, easy to apply and almost always free of fragrance. Their waterproof characteristics allow showering and swimming. On the face, they should be applied and removed every day. A fixing spray is available to maintain the corrective make-up for a whole day. Make-up removers are necessary to clean the skin, with gentle and delicate movements to avoid koebnerization.
- *Dermal pigmentation, cosmetic tattoos* Cosmetic tattoo may be suitable for depigmented lips, especially in black people, and for depigmented nipples. In other vitiligo areas, caution is recommended.



## Depigmentation

In patients with extensive and refractory vitiligo, depigmenting the remaining islands through chemical or physical methods may be cosmetically acceptable. Monobenzone ethyl ester (MBEH) is a derivative of hydroquinone (HQ). Unlike HQ, MBEH almost always causes nearly irreversible depigmentation.<sup>105,106</sup>

The patients with the highest skin phototypes (V and VI), for which the contrast between dark pigmented and white skin is actually disfiguring, may be the best candidates. Patients with phototypes I and II may also obtain better cosmetic improvement using depigmenting agents rather than a repigmenting regimen on exposed areas. The patients must be extensively informed that most approaches lead to irreversible depigmentation.

MBEH is applied topically as a 20% cream. A thin layer of cream should be applied uniformly and rubbed into the pigmented area two to three times daily. Prolonged exposure to sunlight should be avoided during treatment, or a sunscreen should be used, as exposure to sunlight reduces the depigmenting effect. Depigmentation is usually obtained after 1–4 months of treatment. After 4 months of treatment without success, the drug should be discontinued. When the desired degree of depigmentation is obtained, monobenzone should be applied as often as needed to maintain depigmentation (usually only two times weekly).<sup>106</sup>

Mild transient skin irritation or sensitization causing eczema may occur. The treatment should be discontinued if irritation, burning sensation or dermatitis occurs. Ocular side-effects have been rarely reported. Sometimes areas of normal skin distant to the site of application have become depigmented. Monobenzone has been proposed in association with retinoic acid in order to overcome the resistance to treatment.<sup>107</sup>

The Q-switched 755 nm ruby laser has been proposed.<sup>108</sup> It can be used alone or in combination with methoxyphe-nol.<sup>109,110</sup> It destroys melanin and melanin-bearing cells. Cryotherapy has been reported as an inexpensive depigmentation therapy, but due to the risk of scarring, it should be used only by experienced dermatologists.<sup>111–113</sup> However, limited published information is available.<sup>111</sup>

### Expert recommendations: depigmenting agents

- Only patients with extensive disfiguring vitiligo should be treated and only after exploring other possible therapies. The patient should be advised that monobenzone is a potent depigmenting agent and not a cosmetic skin bleach.
- Depigmentation can also be obtained by using a Q-switched ruby laser, alone or in combination with methoxyphenol.

## Psychological interventions

Depigmentation exerts a negative impact on the patient's appearance and self-esteem.<sup>114</sup> Most patients with vitiligo find

their disfigurement moderately or severely intolerable, and suffer from poor body image, low self-esteem and social isolation in both personal and professional relationships. Levels of disability vary according to objective factors (extension and site of the disease, phototype, ethnicity and cultural background).<sup>115,116</sup> The prevalence of psychiatric morbidity ranges from 25% to 30% in Western Europe, with a predominance of fair-skinned subjects, and from 56% to 75% in India, with a predominance of dark-skinned patients.<sup>117</sup> Perceived severity of the disease is more influenced by the patient's personality than by objective traits of the vitiligo.<sup>117</sup> Additional discomforting aspects are the chronic, unpredictable nature of the disease and the lack of a universally effective treatment.<sup>118</sup>

### Expert recommendations: psychological interventions

- Subjective assessment should be included as part of the evaluation of disease severity using an analogue scale with the question: 'How much does your skin disease bother you currently?' or a quality of life questionnaire such as the Dermatology Life Quality Index. If possible, a psychologically oriented interview is further recommended in order to evaluate the perceived influence of the disease and to identify patients for which the psychological support may be useful.
- In the case of a recognized psychosocial impairment, different types of psychological interventions can be proposed. Currently, no specific psychological therapeutic intervention prevails based on published evidence.
- Patients appreciate the opportunity to express difficulties related to their disease and to be listened to and understood. This is particularly relevant in the case of adolescents or dark-skinned individuals with experiences of stigmatization related to cultural background. In this case, besides individual psychosocial therapeutic interventions, community interventions may be necessary.

## Conclusions

Given the importance of charlatanism in the vitiligo field, counselling patients to avoid some therapies of dubious efficacy is a major step. As stated in the Cochrane review on vitiligo,<sup>6</sup> there are many limitations to deriving a valuable algorithm of treatment for all patients with vitiligo based on RCTs. Firstly, RCTs are rare and often lacking important methodological steps or details. Secondly, studies have often been conducted in heterogeneous groups in terms of duration or progression, and mixing localized, segmental and nonsegmental forms. Thirdly, there are many confounding factors (light exposure in long-term interventions, nutritional intake for antioxidants, or awareness on limitation of the Koebner phenomenon).

Nevertheless, a stepwise treatment approach divided by type of vitiligo and extent, which needs modulation by

visibility, age and coping is outlined in Table 4 and the algorithm in Figure 1. A zero line is always possible, meaning no treatment if the disease is not bothering the patient. The environmental factors (occupation, Koebner phenomenon, sustained stress or anxiety) should always be discussed. For SV, triggering neurogenic factors are usually envisaged but good studies are lacking to prove this point. This step-wise approach should be considered as a proposal based mostly on evidence-based medicine data. However, there is much room for modulation and innovation based on this scheme.<sup>119</sup>

The polygenic and multifactorial background in vitiligo should be reflected in more personalized approaches in the future.<sup>119</sup> An early therapeutic intervention before the appearance of leucotrichia is recommended. Cutaneous inflammation may be a shared feature in all cases. Accordingly, a more aggressive anti-inflammatory therapy, including methotrexate, would probably be helpful. If the initial step preceding inflammation comes from a local predisposition of melanocytes to attach poorly to the basement membrane, there are possible targets to improve adhesion mechanisms. The issue of self-renewal ('stemness') aptitude of melanocytes has been raised especially for SV,<sup>119</sup> which clearly benefits from autologous grafting. If impairment of melanocyte survival mechanisms are a cause, growth factor supplementation, such as melanocyte-stimulating hormone (MSH) analogues<sup>120,121</sup> could be used. Improving the antioxidant status of the epidermis has been attempted, but more powerful tools using gene transfer might be used in the future.<sup>122</sup>

When melanocyte loss has been stopped, therapy needs to address repigmentation. New repigmenting therapies are emerging such as helium–neon (He–Ne) lasers and prostaglandin E<sub>2</sub>.<sup>123,124</sup> Recent development in the field of melanocyte precursors are promising. If we can better stimulate the migration of those cells towards the epidermis and understand why they usually stop migrating when becoming pigmented, a major step would be achieved. Newer technologies derived from progenitors or reprogrammed skin cells<sup>125</sup> will probably further increase the possibility of surgical intervention.

## Disclaimer

These guidelines are defined for dermatologists in the clinic and in private practice. Furthermore, they are meant to help health insurance organizations and political decision-makers.

Steps that can be considered part of every physician's general obligations when prescribing drugs (inquiring about allergies and intolerance reactions, as well as identifying potential contraindications) are not reported. It was considered obvious, and not declared, that all patients should be informed about the specific risks associated with any given systemic therapy.

During the preparation of this guideline, further clinical and experimental studies may have been carried out, proving or counteracting the guideline. Consequently, the authors can take no responsibility for dosage or treatment decisions taken in this rapidly changing field. Readers are advised to keep themselves abreast of new data and developments subsequent to the publication of the guidelines.

**Table 4** General outline of management for vitiligo: therapy options, according to the clinical features

Type of vitiligo	Level	Usual management
SV or limited NSV ( $< 2\text{--}3\%$ of body surface)	First line	Avoidance of triggering factors, local therapies (corticosteroids, calcineurin inhibitors)
	Second line	Localized NB-UVB therapy, especially excimer monochromatic lamp or laser
	Third line	Consider surgical techniques if repigmentation cosmetically unsatisfactory on visible areas
NSV	First line	Avoidance of triggering/aggravating factors. Stabilization with NB-UVB therapy, at least 3 months. Optimal duration at least 9 months, if response. Combination with systemic/topical therapies, including reinforcement with localized UVB therapy, possible
	Second line	Systemic steroids (e.g. 3–4-month minipulse therapy) or immunosuppressants if rapidly progressing disease or absence of stabilization under NB-UVB
	Third line	Graft in nonresponding areas especially with high cosmetic impact. However, Koebner phenomenon limits the persistence of grafts. Relative contraindication in areas such as dorsum of hands
	Fourth line	Depigmentation techniques (hydroquinone monobenzyl ether or 4-methoxyphenol alone or associated with Q-switched ruby laser) in nonresponding widespread ( $> 50\%$ ) or highly visible recalcitrant facial/hands vitiligo

A no treatment option (zero line) can be considered in patients with a fair complexion after discussion. For children, phototherapy is limited by feasibility in the younger age group and surgical techniques are rarely proposed before prepubertal age. There is no current recommendation applicable to the case of rapidly progressive vitiligo, not stabilized by ultraviolet (UV) therapy. For all subtypes of disease or lines of treatment, psychological support and counselling, including access to camouflage instructors, is needed. NSV, nonsegmental vitiligo; SV, segmental vitiligo; NB-UVB, narrowband UVB. Table adapted from Ref. 3.

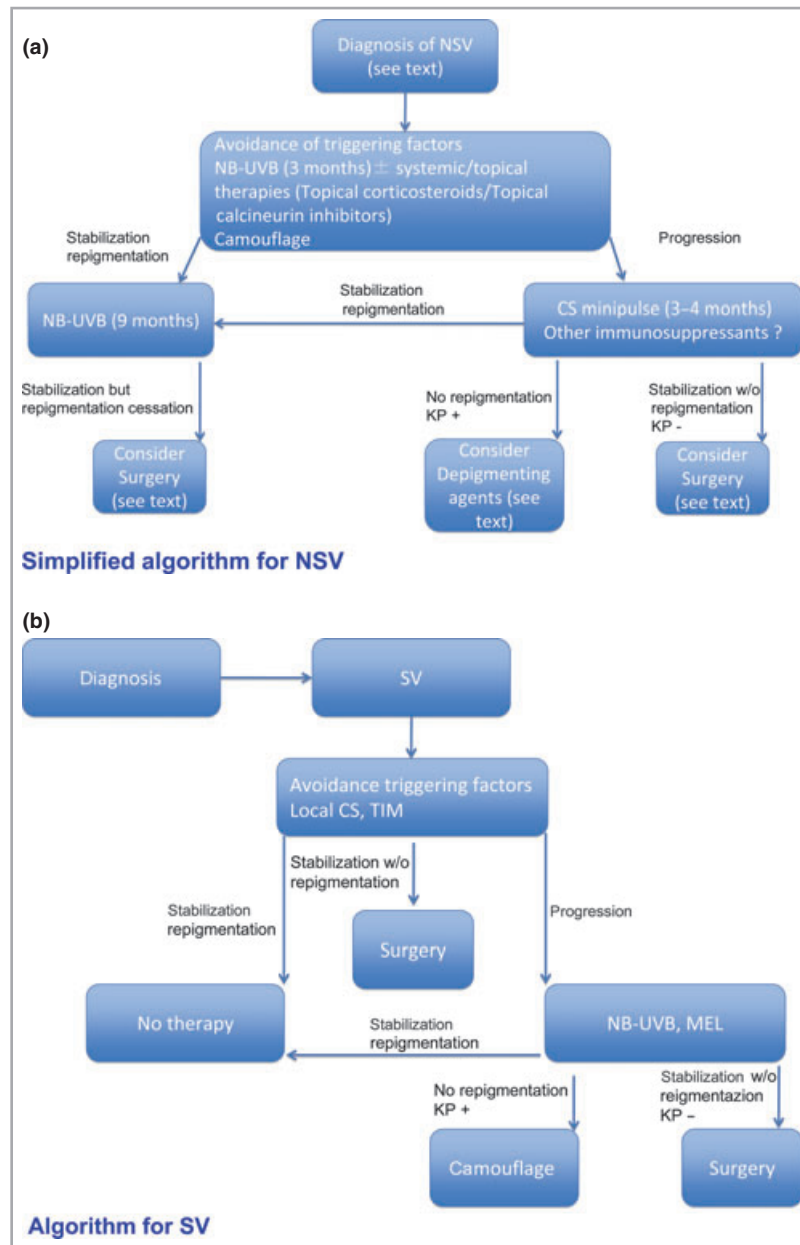


Fig 1. The algorithms represent a handy support for the management of patients with nonsegmental vitiligo (NSV) (a) or segmental vitiligo (SV) (b) during the clinical routine. CS, corticosteroid; KP, Koebner phenomenon; TIM, topical immunomodulating macrolactams; NB-UVB, narrowband ultraviolet B; MEL, monochromatic excimer lamp; w/o, without.

### What's already known about this topic?

- Vitiligo is a disease lacking definitive and completely effective therapies.
- Phototherapy and combined treatments are the most effective treatments.
- Therapy should stop the progression of the lesions and provide complete or almost complete repigmentation to be satisfactory for the patient.

### What does this study add?

- The criteria for treatment have been critically reviewed.
- Evidence-based recommendations (S1) for the treatment of vitiligo have been made.
- A proposal for clinical evaluation, treatment and follow-up has been outlined.

## References

- Taieb A, Picardo M. Epidemiology, definitions and classification. In: *Vitiligo* (Taieb A, Picardo M, eds). Berlin, Heidelberg: Springer, 2010; 13–24.
- Zhang XJ, Liu JB, Gui GP et al. Characteristics of genetic epidemiology and genetic models for vitiligo. *J Am Acad Dermatol* 2004; **51**:383–90.
- Taieb A, Picardo M; VETF members. The definition and assessment of vitiligo: a consensus report of the Vitiligo European Task Force. *Pigment Cell Res* 2007; **20**:27–35.
- Picardo M, Taieb A, eds. *Vitiligo*. Berlin, Heidelberg: Springer, 2010.
- Taieb A, Picardo M. Clinical practice: vitiligo. *N Engl J Med* 2009; **360**:160–9.
- Whitton ME, Pinart M, Batchelor J et al. Interventions for vitiligo. *Cochrane Database Syst Rev* 2010; **1**:CD003263.
- Gawkrodger DJ, Ormerod AL, Shaw L et al. Guideline for the diagnosis and management of vitiligo. *Br J Dermatol* 2008; **159**:1051–76.
- Njoo MD, Spuls PI, Bos JD et al. Nonsurgical repigmentation therapies in vitiligo: meta-analysis of the literature. *Arch Dermatol* 1998; **134**:1532–40.
- Westerhof W, Nieuweboer-Krobotova L, Mulder PGH, Glazenburg EJ. Left–right comparison study of the combination of fluticasone propionate and UV-A vs either fluticasone propionate or UV-A alone for the long-term treatment of vitiligo. *Arch Dermatol* 1999; **135**:1061–6.
- Kumari J. Vitiligo treated with topical clobetasol propionate. *Arch Dermatol* 1984; **120**:631–5.
- Schaffer JV, Bologna JL. The treatment of hypopigmentation in children. *Clin Dermatol* 2003; **21**:296–310.
- Lepe V, Moncada B, Castanedo-Cazares JP et al. A double-blind randomized trial of 0.1% tacrolimus vs 0.05% clobetasol for the treatment of childhood vitiligo. *Arch Dermatol* 2003; **139**:581–5.
- Coskun B, Saral Y, Turgut D. Topical 0.05% clobetasol propionate versus 1% pimecrolimus ointment in vitiligo. *Eur J Dermatol* 2005; **15**:88–91.
- Köse O, Arca E, Kurumlu Z. Mometasone cream versus pimecrolimus cream for the treatment of childhood vitiligo. *J Dermatol Treat* 2010; **21**:133–9.
- Grimes PE, Soriano T, Dytoc MT. Topical tacrolimus for repigmentation of vitiligo. *J Am Acad Dermatol* 2002; **47**:789–91.
- Grimes PE, Morris R, Avaniss-Aghajani E et al. Topical tacrolimus therapy for vitiligo: therapeutic responses and skin messenger RNA expression of proinflammatory cytokines. *J Am Acad Dermatol* 2004; **51**:52–61.
- Lan CCE, Wu CS, Chen GS, Yu HS. FK506 (tacrolimus) and endo-thelin combined treatment induces mobility of melanoblasts: new insights into follicular vitiligo repigmentation induced by topical tacrolimus on sun-exposed skin. *Br J Dermatol* 2011; **164**:490–6.
- Dawid M, Veensalu M, Grassberger M, Wolff K. Efficacy and safety of pimecrolimus cream 1% in adult patients with vitiligo: results of a randomized, double-blind, vehicle-controlled study. *J Dtsch Dermatol Ges* 2006; **4**:942–6.
- Kawalek AZ, Spencer JM, Phelps RG. Combined excimer laser and topical tacrolimus for the treatment of vitiligo: a pilot study. *Dermatol Surg* 2004; **30**:130–5.
- Mehrabi D, Pandya AG. A randomized, placebo-controlled, double-blind trial comparing narrowband UV-B plus 0.1% tacrolimus ointment with narrowband UV-B plus placebo in the treatment of generalized vitiligo. *Arch Dermatol* 2006; **142**:927–9.
- Passeron T, Ostovari N, Zakaria W et al. Topical tacrolimus and the 308-nm excimer laser: a synergistic combination for the treatment of vitiligo. *Arch Dermatol* 2004; **140**:1065–9.
- Ostovari N, Passeron T, Lacour JP, Ortonne JP. Lack of efficacy of tacrolimus in the treatment of vitiligo in the absence of UV-B exposure. *Arch Dermatol* 2006; **142**:252–3.
- Kanwar AJ, Dogra S, Parsad D. Topical tacrolimus for treatment of childhood vitiligo in Asians. *Clin Exp Dermatol* 2004; **29**:589–92.
- Souza Leite RM, Craveiro Leite AA. Two therapeutic challenges: periocular and genital vitiligo in children successfully treated with pimecrolimus cream. *Int J Dermatol* 2007; **46**:986–9.
- Ho N, Pope E, Weinstein M et al. A double-blind randomized placebo-controlled trial of topical tacrolimus 0.1% versus clobetasol propionate 0.05% in childhood vitiligo. *Br J Dermatol* 2011; **165**:626–32.
- Stinco G, Piccirillo F, Forcione M et al. An open randomized study to compare narrow band UVB, topical pimecrolimus and topical tacrolimus in the treatment of vitiligo. *Eur J Dermatol* 2009; **19**:588–93.
- Lotti T, Buggiani G, Troiano M et al. Targeted and combination treatments for vitiligo. Comparative evaluation of different current modalities in 458 subjects. *Dermatol Ther* 2008; **21**:S20–6.
- Hartmann A, Brocker EB, Hamm H. Repigmentation of pretibial vitiligo with calcineurin inhibitors under occlusion. *J Dtsch Dermatol Ges* 2008; **6**:383–5.
- Udompataikul M, Boonsupthip P, Siriwananagat R. Effectiveness of 0.1% topical tacrolimus in adult and children patients with vitiligo. *J Dermatol* 2011; **38**:536–40.
- De D, Kanwar AJ. Tacrolimus-induced hyperpigmentation in a patch of vitiligo. *Skinmed* 2008; **7**:93–4.
- Pathak MA, Fitzpatrick TB. The evolution of photochemotherapy with psoralens and UVA (PUVA): 2000 BC to 1992. *J Photochem Photobiol, B* 1992; **14**:3–22.
- Carrascosa JM, Gardeazabal J, Perez-Ferriols A et al. Consensus document on phototherapy: PUVA therapy and narrow-band UVB therapy. *Actas Dermosifiliogr* 2005; **96**:635–58.
- Wu CS, Lan CC, Wang LF et al. Effects of psoralen plus ultraviolet A irradiation on cultured epidermal cells in vitro and patients with vitiligo in vivo. *Br J Dermatol* 2007; **156**:122–9.
- Bhatnagar A, Kanwar AJ, Parsad D. Comparison of systemic PUVA and NB-UVB in the treatment of vitiligo: an open prospective study. *J Eur Acad Dermatol Venereol* 2007; **21**:638–42.
- Dawe RS, Cameron H, Yule S et al. A randomized controlled trial of narrowband ultraviolet B vs. bath-psoralen plus ultraviolet A photochemotherapy for psoriasis. *Br J Dermatol* 2003; **148**:1194–204.
- Asawanonda P, Kijluakiat J, Korkij W, Sindhupak W. Targeted broadband ultraviolet B phototherapy produces similar responses to targeted narrowband ultraviolet B phototherapy for vitiligo: a randomized, double-blind study. *Acta Derm Venereol* 2008; **88**:376–81.
- Pathak MA, Mosher DB, Fitzpatrick TB. Safety and therapeutic effectiveness of 8-methoxypsoralen, 4,5,8-trimethylpsoralen, and psoralen in vitiligo. *Natl Cancer Inst Monogr* 1984; **66**:165–73.
- Yones SS, Palmer RA, Garibaldinos TM, Hawk JL. Randomized double-blind trial of treatment of vitiligo: efficacy psoralen UVA therapy versus narrowband UVB therapy. *Arch Dermatol* 2007; **143**:578–84.
- Morrison WL, Marwaha S, Beck L et al. PUVA-induced phototoxicity: incidence and causes. *J Am Acad Dermatol* 1997; **36**:183–6.
- Ortel B, Tanew A, Honigsmann H. Treatment of vitiligo with khellin and ultraviolet A. *J Am Acad Dermatol* 1988; **18**:693–701.
- Orecchia G, Perfetti L. Photochemotherapy with topical khellin and sunlight in vitiligo. *Dermatology* 1992; **184**:120–3.
- Anbar TS, Westerhof W, Abdel-Rahman AT, El-Khayyat MA. Evaluation of the effects of NB-UVB in both segmental and

- non-segmental vitiligo affecting different body sites. *Photodermatol Photoimmunol Photomed* 2006; **22**:157–63.
- 43 Diffey BL, Farr PM. The challenge of follow-up in narrowband ultraviolet B phototherapy. *Br J Dermatol* 2007; **157**:344–9.
  - 44 Njoo MD, Bos JD, Westerhof W. Treatment of generalized vitiligo in children with narrow-band (TL-01) UVB radiation therapy. *J Am Acad Dermatol* 2000; **42**:245–55.
  - 45 Westerhof W, Nieuweboer-Krobotova L. Treatment of vitiligo with UV-B radiation vs topical psoralen plus UV-A. *Arch Dermatol* 1997; **133**:1525–8.
  - 46 Parsad D, Kanwar AJ, Kumar B. Psoralen–ultraviolet A vs. narrow-band ultraviolet B phototherapy for the treatment of vitiligo. *J Eur Acad Dermatol Venereol* 2006; **20**:175–7.
  - 47 Baltas E, Csoma Z, Ignacz F *et al.* Treatment of vitiligo with the 308 nm xenon chloride excimer laser. *Arch Dermatol* 2002; **138**:1619–20.
  - 48 Bianchi B, Campolmi P, Mavilla L *et al.* Monochromatic excimer light (308 nm): an immunohistochemical study of cutaneous T cells and apoptosis related molecules in psoriasis. *J Eur Acad Dermatol Venereol* 2003; **17**:408–13.
  - 49 Casacci M, Thomas P, Pacifico A *et al.* Comparison between 308-nm monochromatic excimer light and narrowband UVB phototherapy (311–313 nm) in the treatment of vitiligo – a multicentre controlled study. *J Eur Acad Dermatol Venereol* 2007; **21**:956–63.
  - 50 Leone G, Iacovelli P, Paro Vidolin A, Picardo M. Monochromatic excimer light 308 nm in the treatment of vitiligo: a pilot study. *J Eur Acad Dermatol Venereol* 2003; **17**:531–7.
  - 51 Pacifico A, Leone G. Photo(chemo)therapy in vitiligo. *Photodermatol Photoimmunol Photomed* 2011; **27**:261–77.
  - 52 Sassi F, Cazzaniga S, Tessari G *et al.* Randomized controlled trial comparing the effectiveness of 308 nm excimer laser alone or in combination with topical hydrocortisone 17-butyrate cream in the treatment of vitiligo of the face and neck. *Br J Dermatol* 2008; **159**:1186–91.
  - 53 Castanedo-Cazares JP, Lepe V, Moncada B. Repigmentation of chronic vitiligo lesions by following tacrolimus plus ultraviolet B narrow band. *Photodermatol Photoimmunol Photomed* 2003; **19**:35–6.
  - 54 Fai D, Cassano N, Vena GA. Narrowband UVB phototherapy combined with tacrolimus ointment in vitiligo: a review of 110 patients. *J Eur Acad Dermatol Venereol* 2007; **21**:916–20.
  - 55 Nordal E, Guleng G, Rønnevig J. Treatment of vitiligo with narrowband-UVB (TL01) combined with tacrolimus ointment (0.1%) vs. placebo ointment, a randomized right/left double-blind comparative study. *J Eur Acad Dermatol Venereol* 2011; **25**:1440–3.
  - 56 Esfandiarpour I, Ekhlesi A, Farajzadeh S, Shamsadini S. The efficacy of pimecrolimus 1% cream plus narrow-band ultraviolet B in the treatment of vitiligo: a double-blind, placebo-controlled clinical trial. *J Dermatolog Treat* 2009; **20**:14–18.
  - 57 Baysal V, Yildirim M, Erel A, Kesig D. Is the combination of calcipotriol and PUVA effective in vitiligo? *J Eur Acad Dermatol Venereol* 2003; **17**:299–302.
  - 58 Leone G, Pacifico A, Iacovelli P, Paro Vidolin A. Tacalcitol and narrow-band phototherapy in patients with vitiligo. *Clin Exp Dermatol* 2006; **31**:200–5.
  - 59 Tang LY, Fu WW, Xiang LH *et al.* Topical tacalcitol and 308 nm monochromatic excimer light: a synergistic combination for the treatment of vitiligo. *Photodermatol Photoimmunol Photomed* 2006; **22**:310–14.
  - 60 Goldinger SM, Dummer R, Schmid P *et al.* Combination of 308 nm xenon chloride excimer laser and topical calcipotriol in vitiligo. *J Eur Acad Dermatol Venereol* 2007; **21**:504–8.
  - 61 Oh SH, Kim T, Jee H *et al.* Combination treatment of non-segmental vitiligo with a 308-nm xenon chloride excimer laser and topical high-concentration tacalcitol: a prospective, single-blinded, paired, comparative study. *J Am Acad Dermatol* 2011; **65**:428–30.
  - 62 Parsad D, Saini R, Nagpal R. Calcipotriol in vitiligo: a preliminary study. *Pediatr Dermatol* 1999; **16**:317–20.
  - 63 Schallreuter KU, Wood JM, Lemke KR, Levenig C. Treatment of vitiligo with a topical application of pseudocatalase and calcium in combination with short-term UVB exposure: a case study of 33 patients. *Dermatology* 1995; **190**:223–9.
  - 64 Bakis-Petsoglou S, Le Guay JL, Wittal R. A randomized, double-blinded, placebo-controlled trial of pseudocatalase cream and narrowband ultraviolet B in the treatment of vitiligo. *Br J Dermatol* 2009; **161**:910–17.
  - 65 Dell’Anna ML, Mastrofrancesco A, Sala R *et al.* Antioxidants and narrow band-UVB in the treatment of vitiligo: a double-blind placebo controlled trial. *Clin Exp Dermatol* 2007; **32**:631–6.
  - 66 Middelkamp-Hup MA, Bos JD, Riuz-Diaz F *et al.* Treatment of vitiligo vulgaris with narrow band UVB and oral *Polypodium leucotomos* extract: a randomized double-blind placebo controlled study. *J Eur Acad Dermatol Venereol* 2007; **21**:942–50.
  - 67 Hann SK, Im S, Park YK, Hur W. Repigmentation of leukotrichia by epidermal grafting and systemic psoralen plus UVA. *Arch Dermatol* 1992; **128**:998–9.
  - 68 Tsukamoto K, Osada A, Kitamura R *et al.* Approaches to repigmentation of vitiligo skin: new treatment with ultrasonic abrasion, seed-grafting and psoralen plus ultraviolet A therapy. *Pigment Cell Res* 2002; **15**:331–4.
  - 69 Anbar TS, Westerhof W, Abdel-Rahman T *et al.* Effect of one session of ER:YAG laser ablation plus topical 5-Fluorouracil on the outcome of short-term NB-UVB phototherapy in the treatment of non-segmental vitiligo: a left–right comparative study. *Photodermatol Photoimmunol Photomed* 2008; **24**:322–9.
  - 70 Van Geel N, Ongenaes K, De Mil M *et al.* Double-blind placebo controlled study of autologous transplanted epidermal cell suspensions for repigmenting vitiligo. *Arch Dermatol* 2004; **140**:1203–8.
  - 71 Bayoumi W, Fontas E, Silard L *et al.* Effect of a preceding laser dermabrasion on the outcome of combined therapy with narrowband ultraviolet B and potent topical steroids for treating nonsegmental vitiligo in resistant localizations. *Br J Dermatol* 2012; **166**:208–11.
  - 72 Shin J, Lee JS, Hann SK, Oh SH. Combination treatment by 10 600 nm ablative fractional carbon dioxide laser and narrowband ultraviolet B in refractory nonsegmental vitiligo: a prospective, randomized half-body comparative study. *Br J Dermatol* 2012; **166**:658–61.
  - 73 Barman KD, Khaitan BK, Verma KK. A comparative study of punch grafting followed by topical corticosteroid versus punch grafting followed by PUVA therapy in stable vitiligo. *Dermatol Surg* 2004; **30**:49–53.
  - 74 Radmanesh M, Saedi K. The efficacy of combined PUVA and low-dose azathioprine for early and enhanced repigmentation in vitiligo patients. *J Dermatolog Treat* 2006; **17**:151–3.
  - 75 Pasricha JS, Seetharam KA, Dashore A. Evaluation of five different regimes for the treatment of vitiligo. *Indian J Dermatol Venereol Leprol* 1989; **55**:18–21.
  - 76 Pasricha JS, Khaitan BK. Oral mini-pulse therapy with betamethasone in vitiligo patients having extensive or fast-spreading disease. *Int J Dermatol* 1993; **32**:753–7.
  - 77 Radakovic-Fijan S, Furnsinn-Fridl AM, Honigsmann H, Tanew A. Oral dexamethasone pulse treatment for vitiligo. *J Am Acad Dermatol* 2001; **44**:814–17.
  - 78 Kim SM, Lee HS, Hann SK. The efficacy of low-dose oral corticosteroids in the treatment of vitiligo patients. *Int J Dermatol* 1999; **38**:546–50.

- 79 Rath N, Kar HK, Sabhnani S. An open labeled, comparative clinical study on efficacy and tolerability of oral minipulse of steroid (OMP) alone, OMP with PUVA and broad/narrow band UVB phototherapy in progressive vitiligo. *Indian J Dermatol Venereol Leprol* 2008; **74**:357–60.
- 80 Gokhale BB. Cyclophosphamide and vitiligo. *Int J Dermatol* 1979; **18**:92.
- 81 Gupta AK, Ellis CN, Nickoloff BJ *et al.* Oral cyclosporine in the treatment of inflammatory and noninflammatory dermatoses. A clinical and immunopathologic analysis. *Arch Dermatol* 1990; **126**:339–50.
- 82 Rigopoulos D, Gregoriou S, Larios G *et al.* Etanercept in the treatment of vitiligo. *Dermatology* 2007; **215**:84–5.
- 83 Smith DI, Heffernan MP. Vitiligo after the resolution of psoriatic plaques during treatment with adalimumab. *J Am Acad Dermatol* 2008; **58**:S50–1.
- 84 Ramírez-Hernández M, Marras C, Martínez-Escribano JA. Infliximab-induced vitiligo. *Dermatology* 2005; **210**:79–80.
- 85 Dell'Anna ML, Picardo M. A review and a new hypothesis for non-immunological pathogenetic mechanisms in vitiligo. *Pigment Cell Res* 2006; **19**:406–11.
- 86 Picardo M, Dell'Anna ML. Vitamins and antioxidants: topical and systemic. In: *Vitiligo* (Picardo M, Taieb A, eds). Berlin: Springer, 2010; 369–74.
- 87 Akyol M, Celik VK, Ozcelik S *et al.* The effects of vitamin E on the skin lipid peroxidation and the clinical improvement in vitiligo patients treated with PUVA. *Eur J Dermatol* 2002; **12**:24–6.
- 88 Parsad D, Pandhi R, Juneja A. Effectiveness of oral *Ginkgo biloba* in treating limited, slowly spreading vitiligo. *Clin Exp Dermatol* 2002; **28**:285–7.
- 89 Schallreuter KU, Kruger C, Wurfel BA *et al.* From basic research to bedside: efficacy of topical treatment with pseudo catalase PC-KUS in 71 children with vitiligo. *Int J Dermatol* 2008; **188**:215–18.
- 90 Sanclemente G, Garcia JJ, Zuleta JJ *et al.* A double-blind, randomized trial of 0.05% betamethasone vs topical catalase/dismutase superoxide in vitiligo. *J Eur Acad Dermatol Venereol* 2008; **22**:1359–64.
- 91 Herberg S, Ezzedine K, Guinot C *et al.* Antioxidant supplementation increases the risk of skin cancers in women but not in men. *J Nutr* 2007; **137**:2098–105.
- 92 Njoo MD, Bos JD, Westerhof W, Bossuyt PM. A systematic review of autologous transplantation methods in vitiligo. *Arch Dermatol* 1998; **134**:1543–9.
- 93 Gauthier Y. Complications and limitations of melanocyte transplantation. In: *Surgical Management of Vitiligo* (Gupta S, Olsson M, Kanwar AJ, Ortonne JP, eds). Oxford: Blackwell Publishing, 2007; 144–7.
- 94 Olsson MJ, Juhlin L. Long-term follow-up of leucoderma patients treated with transplants of autologous cultured melanocytes, ultra-thin epidermal sheets and basal cell layer suspension. *Br J Dermatol* 2002; **147**:893–904.
- 95 Falabella R. Surgical treatment of vitiligo. Why, when and how? *J Eur Acad Dermatol Venereol* 2003; **17**:518–20.
- 96 Olsson MJ. What are the needs for transplantation treatment in vitiligo, and how good is it? *Arch Dermatol* 2004; **104**:1273–4.
- 97 Gupta S, Narang T, Olsson MJ, Ortonne JP. Surgical management of vitiligo and other leukodermas: evidence-based practice guidelines. In: *Surgical Management of Vitiligo* (Gupta S, Olsson M, Kanwar AJ, Ortonne JP, eds). Oxford: Blackwell Publishing, 2007; 69–79.
- 98 Parsad D, Gupta S. Standard guidelines of care for vitiligo surgery. *Indian J Dermatol Venereol Leprol* 2008; **74**:37–45.
- 99 Lee DY, Choi SC. A proposal for the treatment guideline in segmental vitiligo. *Int J Dermatol* 2012; doi:10.1111/j.1365-4632.2010.04694.x [Epub ahead of print].
- 100 Tanioka M, Yamamoto Y, Kato M, Miyachi Y. Camouflage for patients with vitiligo vulgaris improved their quality of life. *J Cosmet Dermatol* 2010; **9**:72–5.
- 101 DePase A. 'La Voce dei Pazienti'. *Evidence Based Dermatology*. Milan: Masson Publisher, 2003.
- 102 Ongenaes K, Dierckxsens L, Brochez L *et al.* Quality of life and stigmatization profile in a cohort of vitiligo patients and effect of the use of camouflage. *Dermatology* 2005; **210**:279–85.
- 103 Savin J. The hidden face of dermatology. *Clin Exp Dermatol* 1993; **18**:393–5.
- 104 De Cuyper C. Permanent makeup: indications and complications. *Clin Dermatol* 2008; **26**:30–4.
- 105 Njoo MD, Vodegel RM, Westerhof W. Depigmentation therapy in vitiligo universalis with topical 4-methoxyphenol and the Q-switched ruby laser. *J Am Acad Dermatol* 2000; **42**:760–9.
- 106 Rao J, Fitzpatrick RE. Use of the Q-switched 755-nm alexandrite laser to treat recalcitrant pigment after depigmentation therapy for vitiligo. *Dermatol Surg* 2004; **30**:1043–5.
- 107 Kasraee B, Fallahi MR, Ardekani GS *et al.* Retinoic acid synergistically enhances the melanocytotoxic and depigmenting effects of monobenzylether of hydroquinone in black guinea pig skin. *Exp Dermatol* 2006; **15**:509–14.
- 108 Kim YJ, Chung BS, Choi KC. Depigmentation therapy with Q-switched ruby laser after tanning in vitiligo universalis. *Dermatol Surg* 2001; **27**:969–70.
- 109 Nordlund JJ. Depigmentation for the treatment of extensive vitiligo. In: *Vitiligo* (Hann SK, Nordlund JJ, eds). Oxford: Blackwell Science, 2000; 207–13.
- 110 Solano F, Briganti S, Picardo M, Ghanem G. Hypopigmenting agents: an updated review on biological, chemical and clinical aspects. *Pigment Cell Res* 2006; **19**:550–71.
- 111 Alghamdi K, Kumar A. Depigmentation therapies for normal skin in vitiligo universalis. *J Eur Acad Dermatol Venereol* 2011; **25**:749–57.
- 112 Radmanesh M. Depigmentation of the normally pigmented patches in universal vitiligo patients with cryotherapy. *J Eur Acad Dermatol Venereol* 2000; **14**:149–52.
- 113 Di Nuzzo S, Masotti A. Depigmentation therapy in vitiligo universalis with cryotherapy and 4-hydroxyanisole. *Clin Exp Dermatol* 2010; **35**:215–16.
- 114 Linthorst Homan MW, Spuls PI, De Korte J *et al.* The burden of vitiligo: patient characteristics associated with quality of life. *J Am Acad Dermatol* 2009; **61**:411–20.
- 115 Thompson AR, Clarke SA, Newell RJ, Gawkrödger; Appearance Research Collaboration. Vitiligo linked to stigmatization in British South Asian women: a qualitative study of the experiences of living with vitiligo. *Br J Dermatol* 2010; **163**:481–6.
- 116 Kostoupolou P, Taieb A. Psychological interventions. In: *Vitiligo* (Picardo M, Taieb A, eds). Berlin: Springer, 2009; 433–5.
- 117 Kostoupolou P, Juoary T, Quintard B *et al.* Objective vs. subjective factors in the psychological impact of vitiligo: the experience from a French referral centre. *Br J Dermatol* 2009; **161**:128–33.
- 118 Talsania N, Lamb B, Bewley A. Vitiligo is more than skin deep: a survey of members of the Vitiligo Society. *Clin Exp Dermatol* 2009; **35**:736–9.
- 119 Taieb A. Intrinsic and extrinsic pathomechanisms in vitiligo. *Pigment Cell Res* 2000; **13**:41–7.
- 120 Harms J, Lautenschlager S, Minder CE, Minder EI. An alpha-melanocyte-stimulating hormone analogue in erythropoietic protoporphyria. *N Engl J Med* 2009; **360**:306–7.
- 121 Bondanza S, Maurelli R, Paterna P *et al.* Keratinocyte cultures from involved skin in vitiligo patients show an impaired *in vitro* behaviour. *Pigment Cell Res* 2007; **20**:288–300.
- 122 Rezvani HR, Cario-Andrè M, Pain C *et al.* Protection of normal human reconstructed epidermis from UV by catalase overexpression. *Cancer Gene Ther* 2006; **14**:174–86.

- 123 Kapoor R, Phiske MM, Jerajani HR. Evaluation of safety and efficacy of topical prostaglandin E2 in treatment of vitiligo. *Br J Dermatol* 2009; **160**:861–3.
- 124 Lan CC, Wu CS, Chiou MH *et al.* Low-energy helium–neon laser induces locomotion of the immature melanoblasts and promotes melanogenesis of the more differentiated melanoblasts: recapitulation of vitiligo repigmentation in vitro. *J Invest Dermatol* 2006; **126**:2119–26.
- 125 Takahashi K, Tanabe K, Ohnuki M. Induction of pluripotent stem cells from adult human fibroblasts by defined factors. *Cell* 2007; **131**:861–72.